



# eXceed Aligners Case Presentation

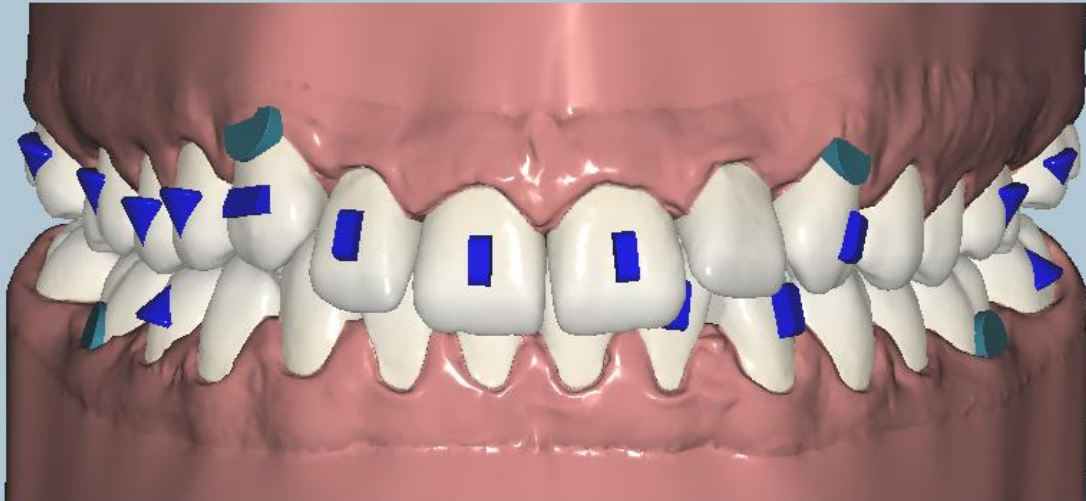
November 15, 2020

Courtesy of Dr. Dr. Artem Kuznetcov

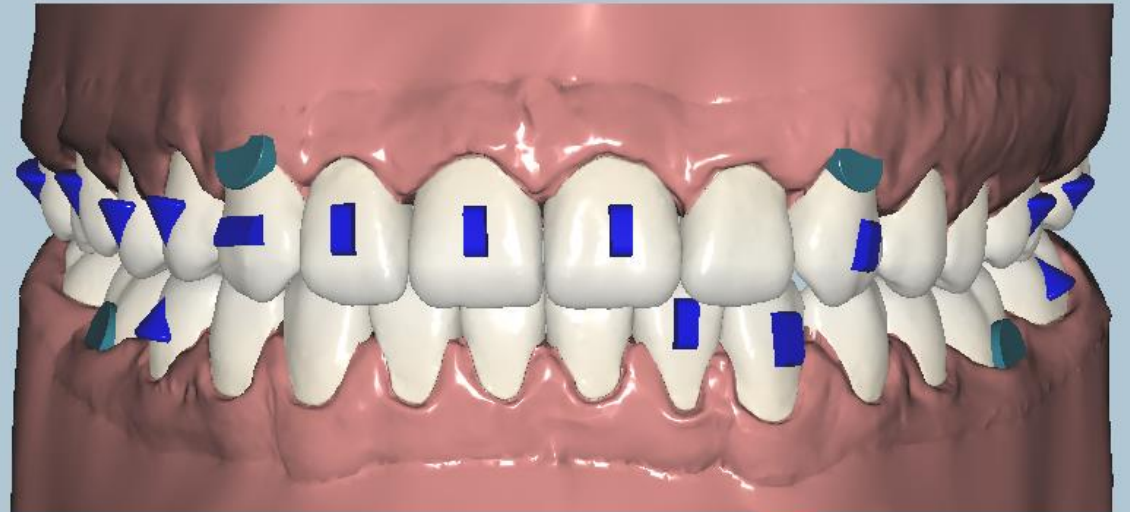
## Case Details

- Patient details: Female, 15 years old
- Chief patient complaints: Aesthetics
- Treatment plan: Correction of crowding, high canine position, incisor retroclination, class II relationship on the right side.
- Aligners: upper – 33 + 5 aligners, lower – 18 + 10 aligners
- Start date: June 2019
- Finish date: December 2020
- Treatment time: 12.5 months + revision 5 months

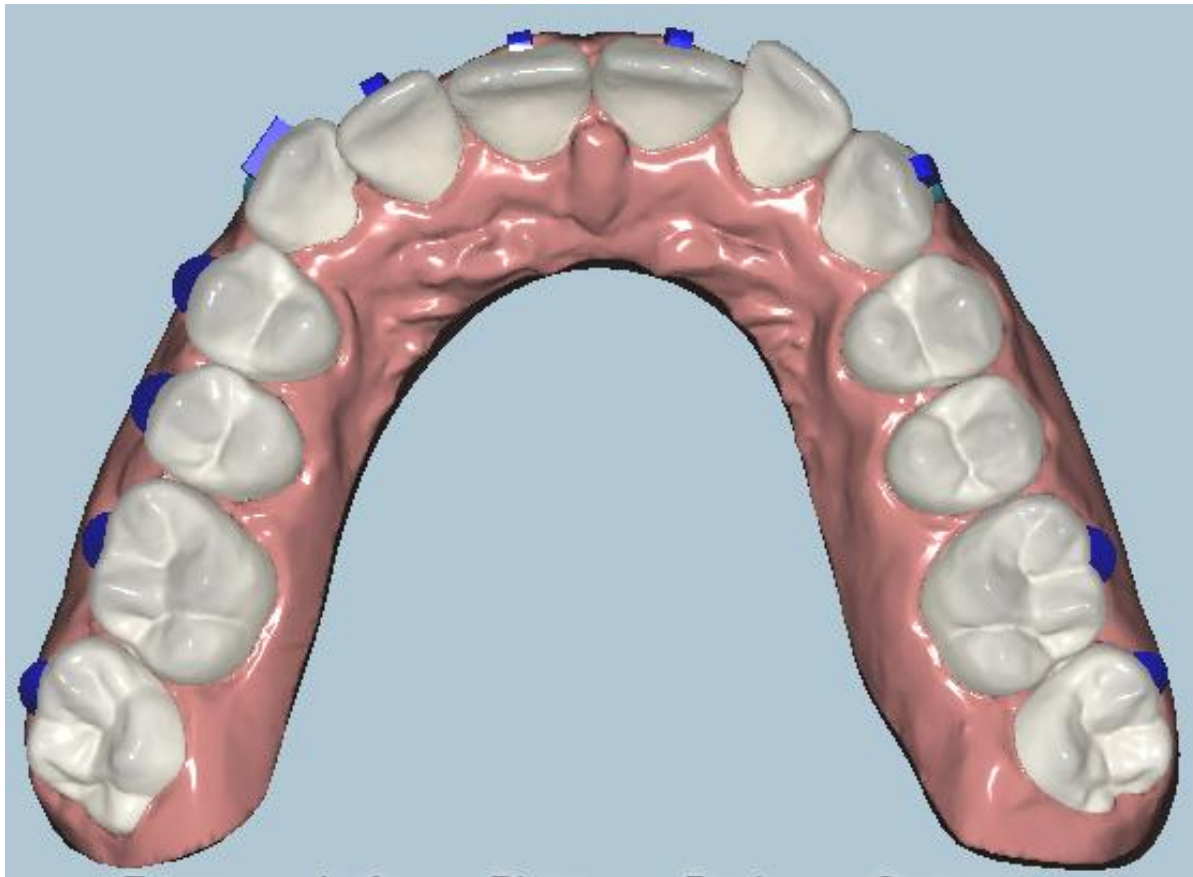
Before



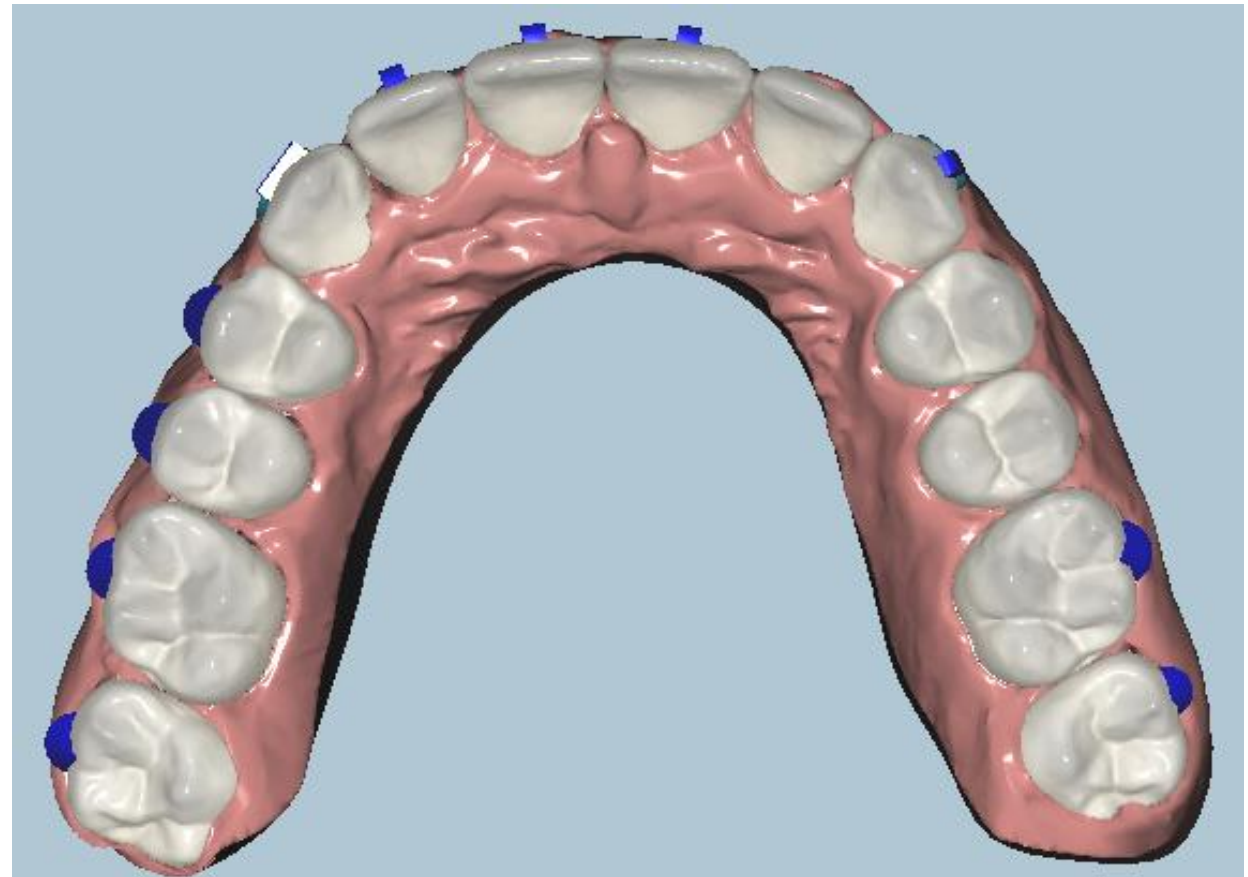
After



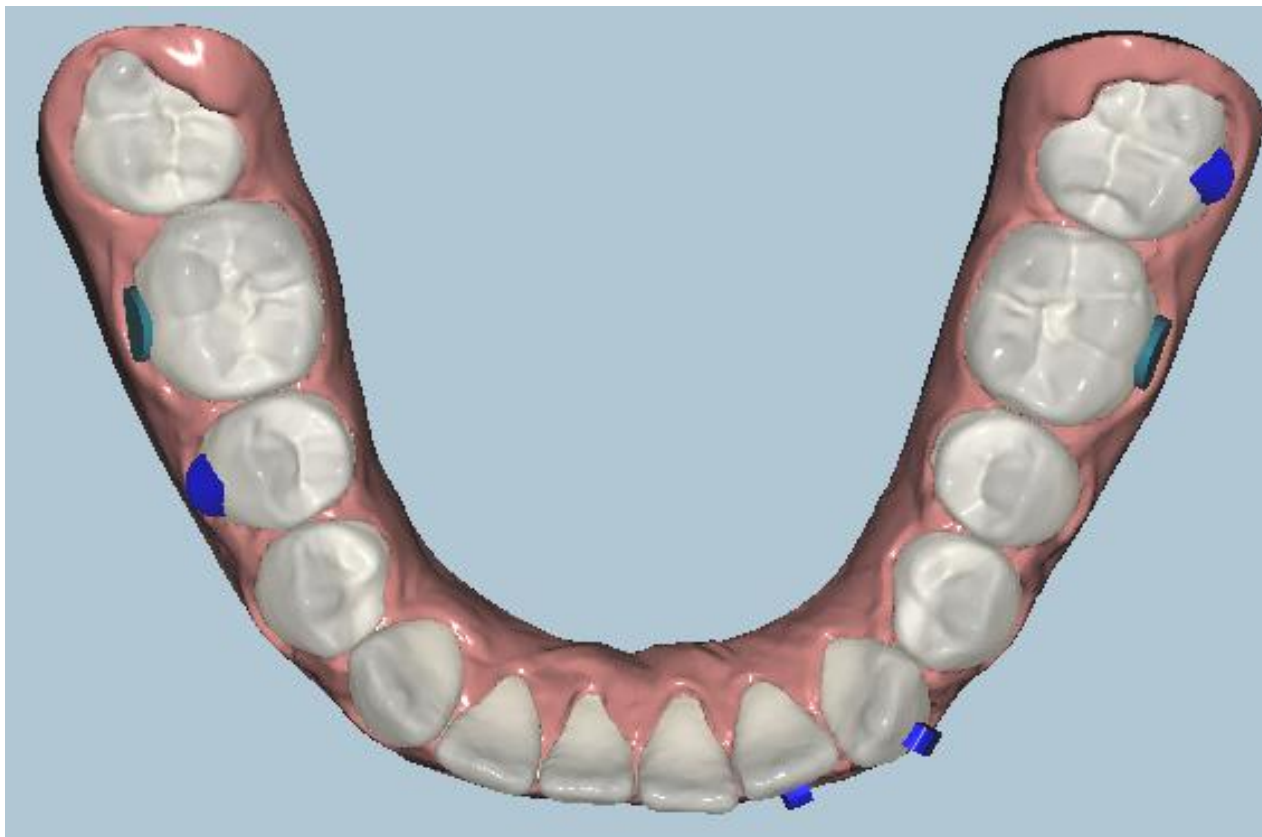
Before



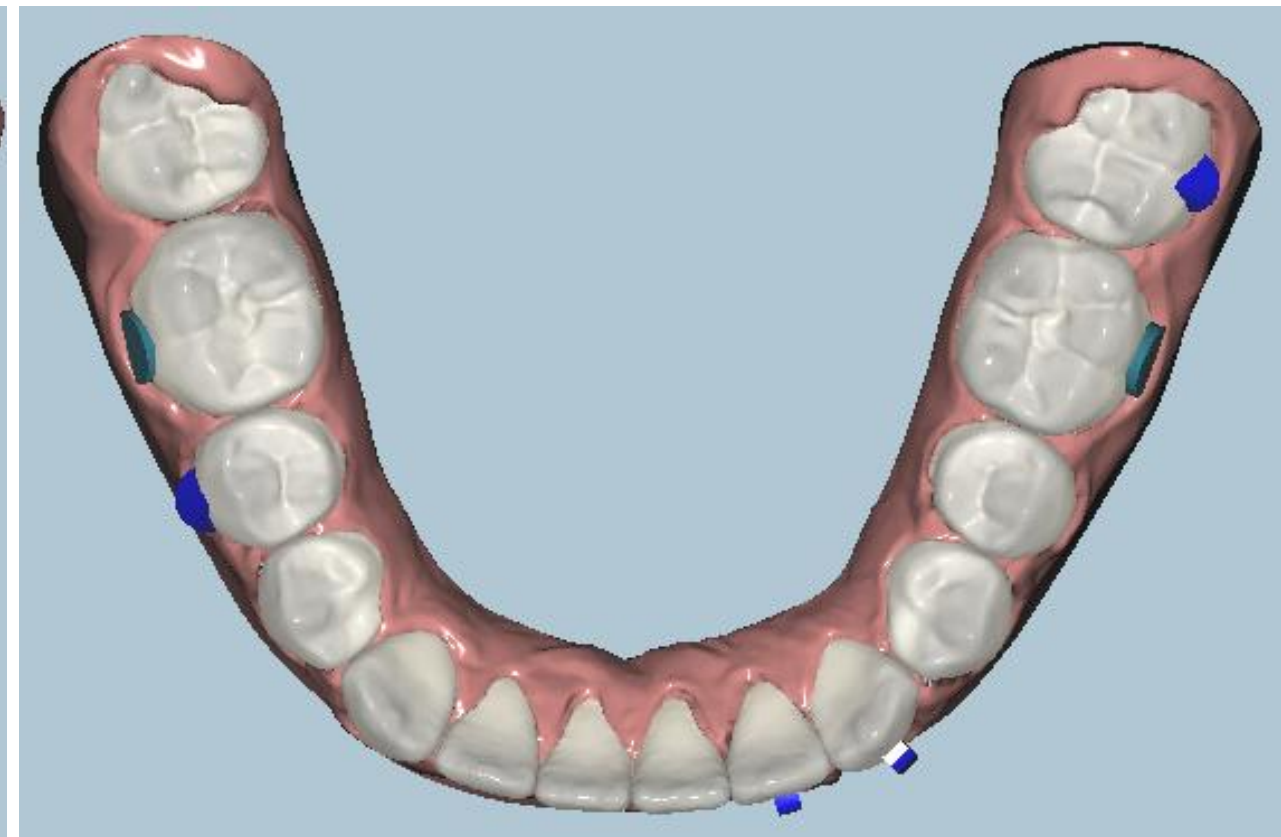
After



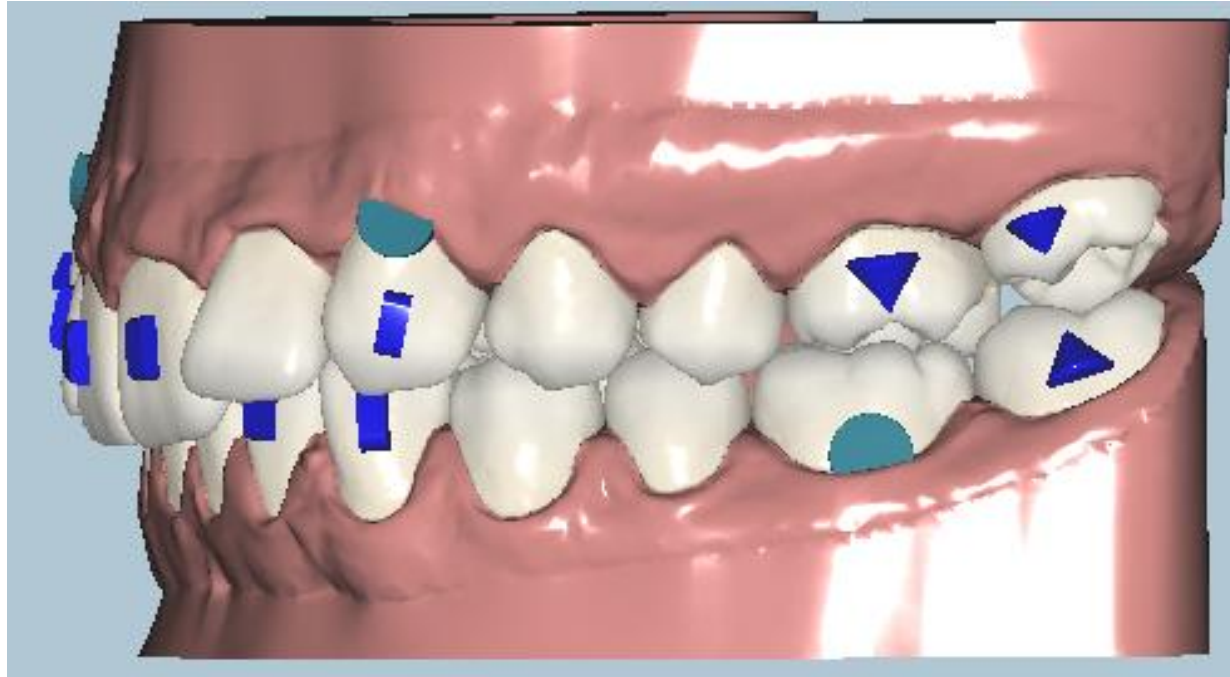
Before



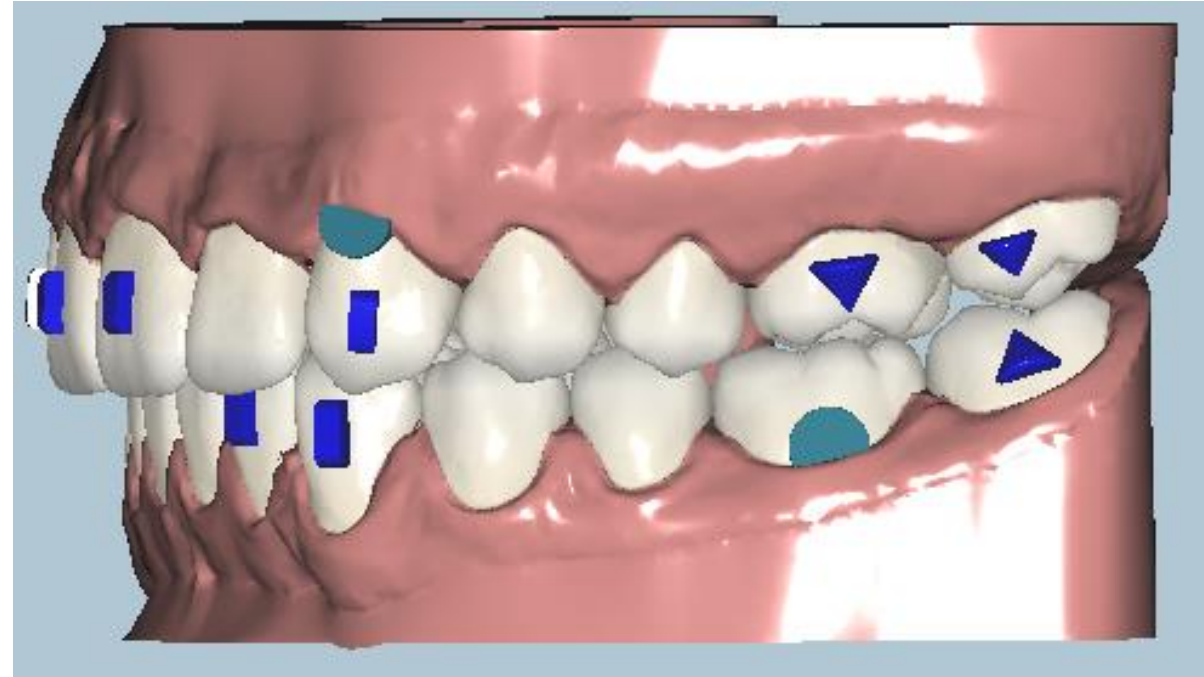
After



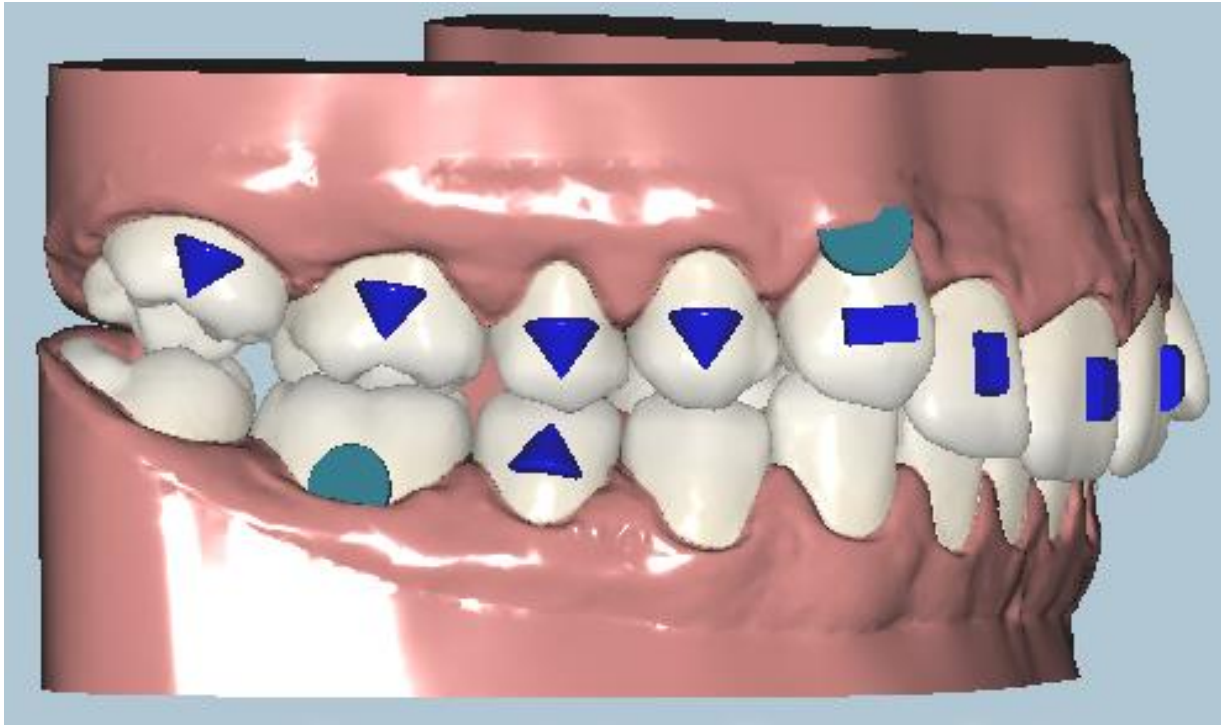
Before



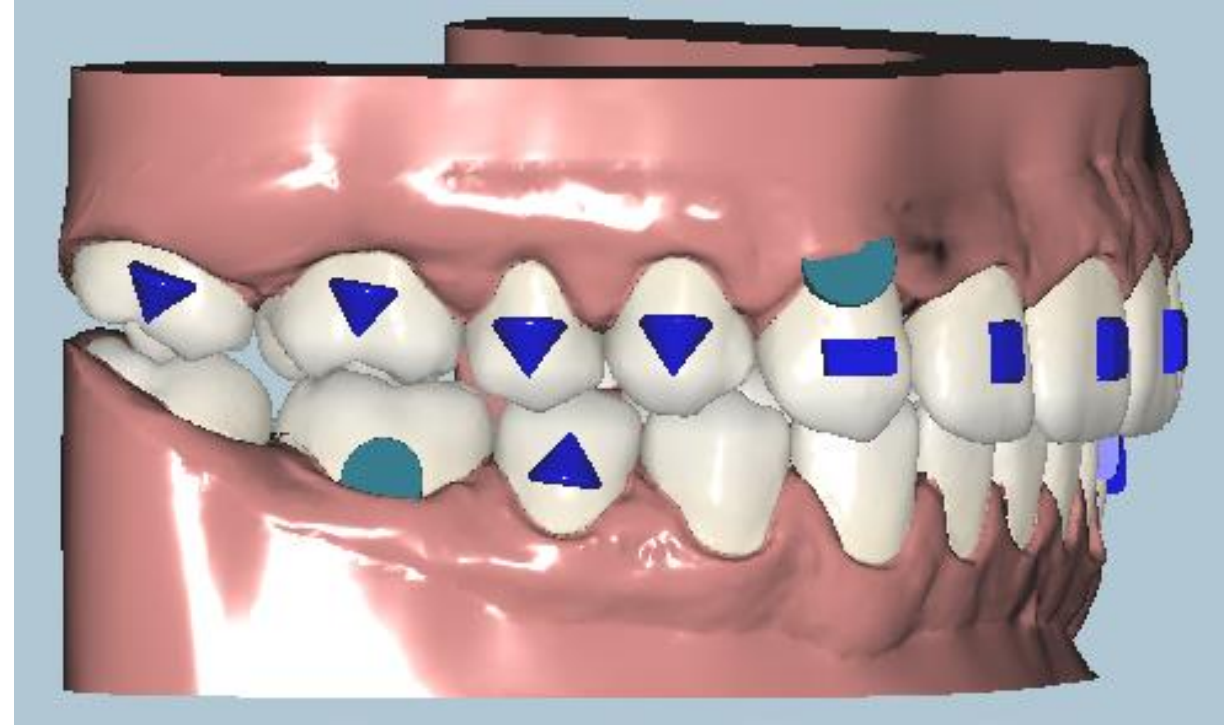
After



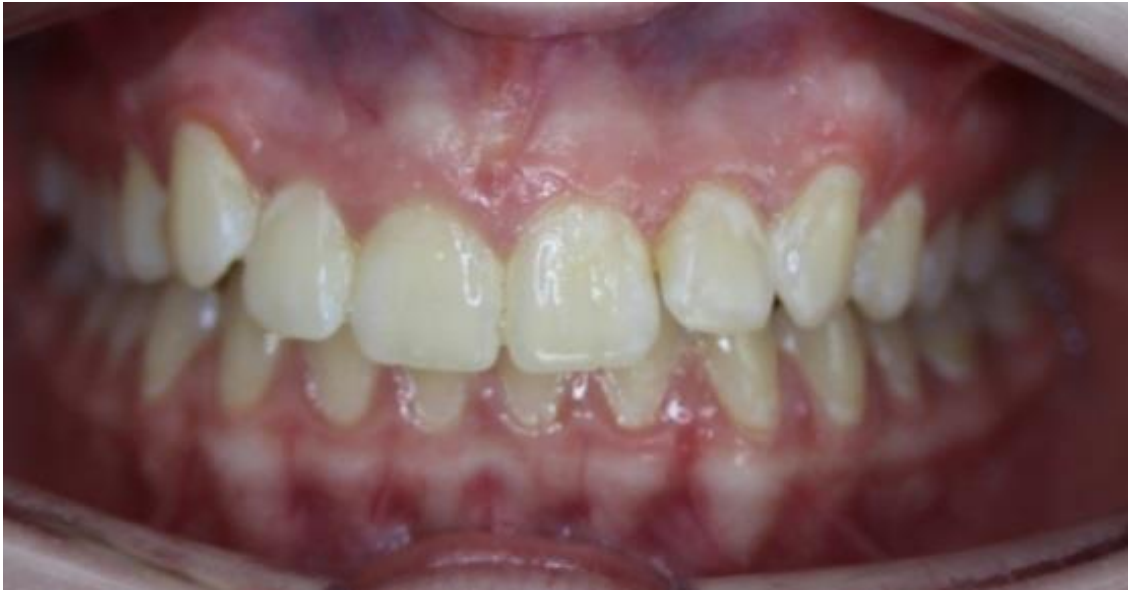Before



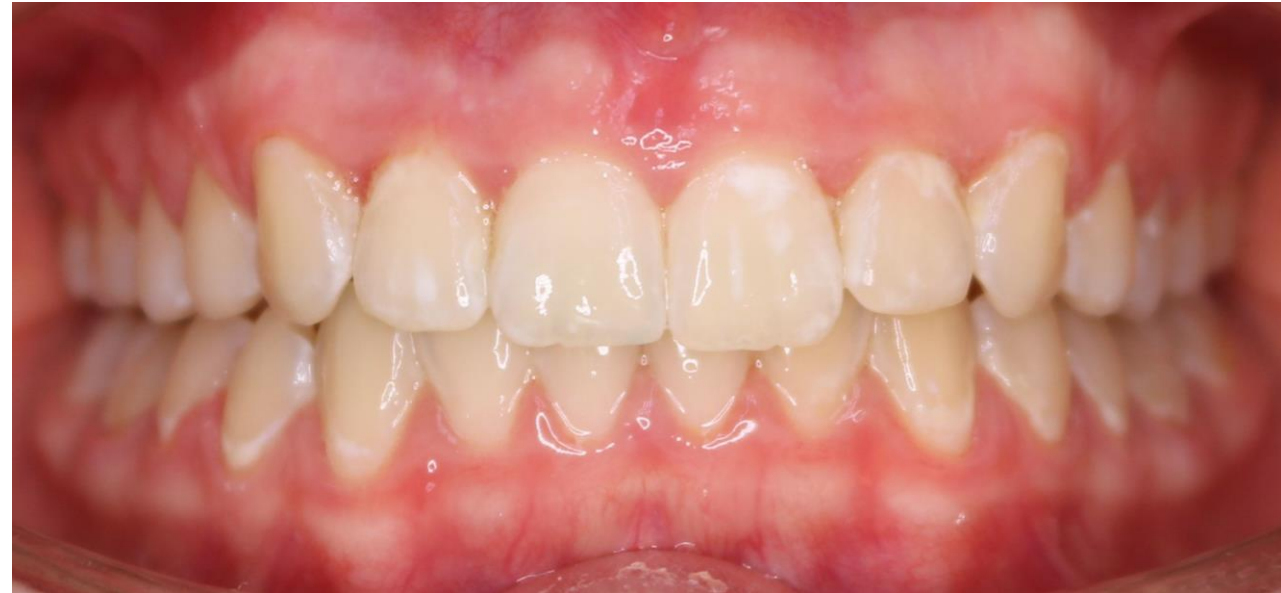After



Before

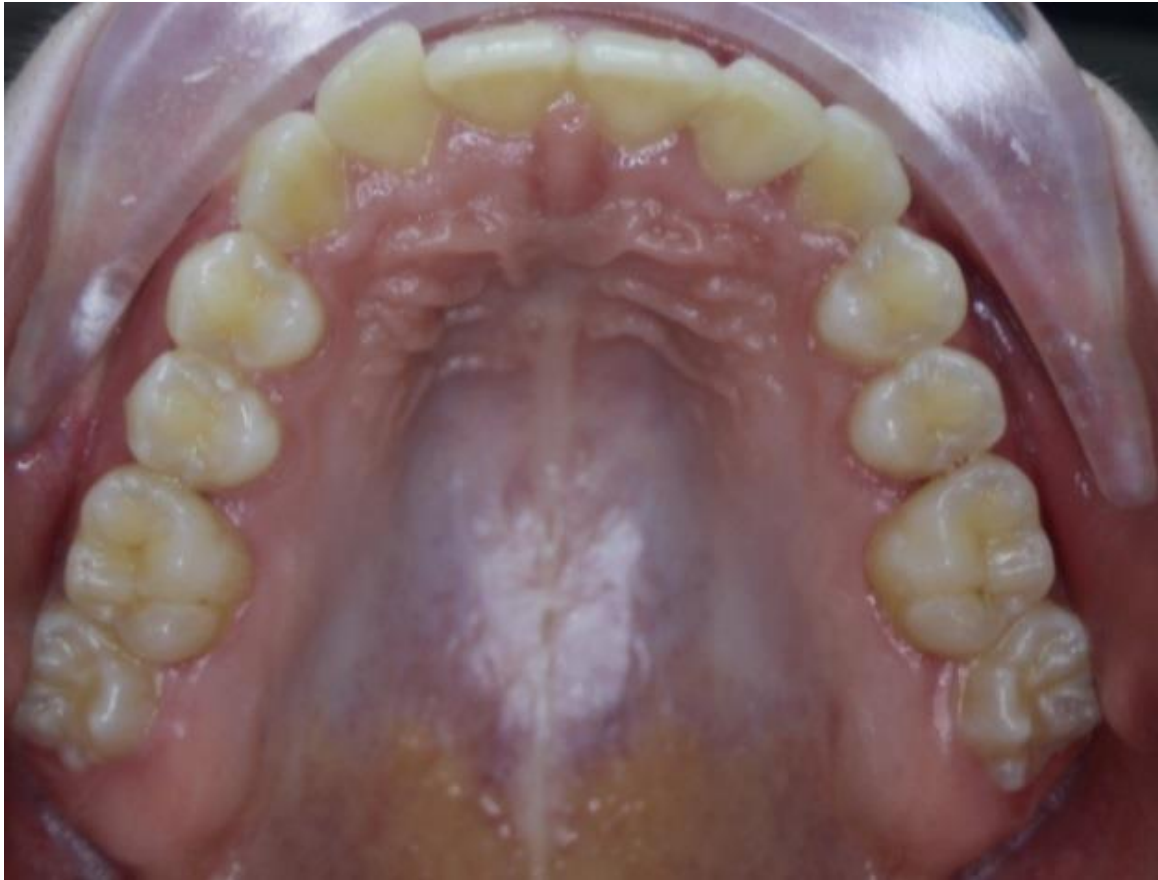


After

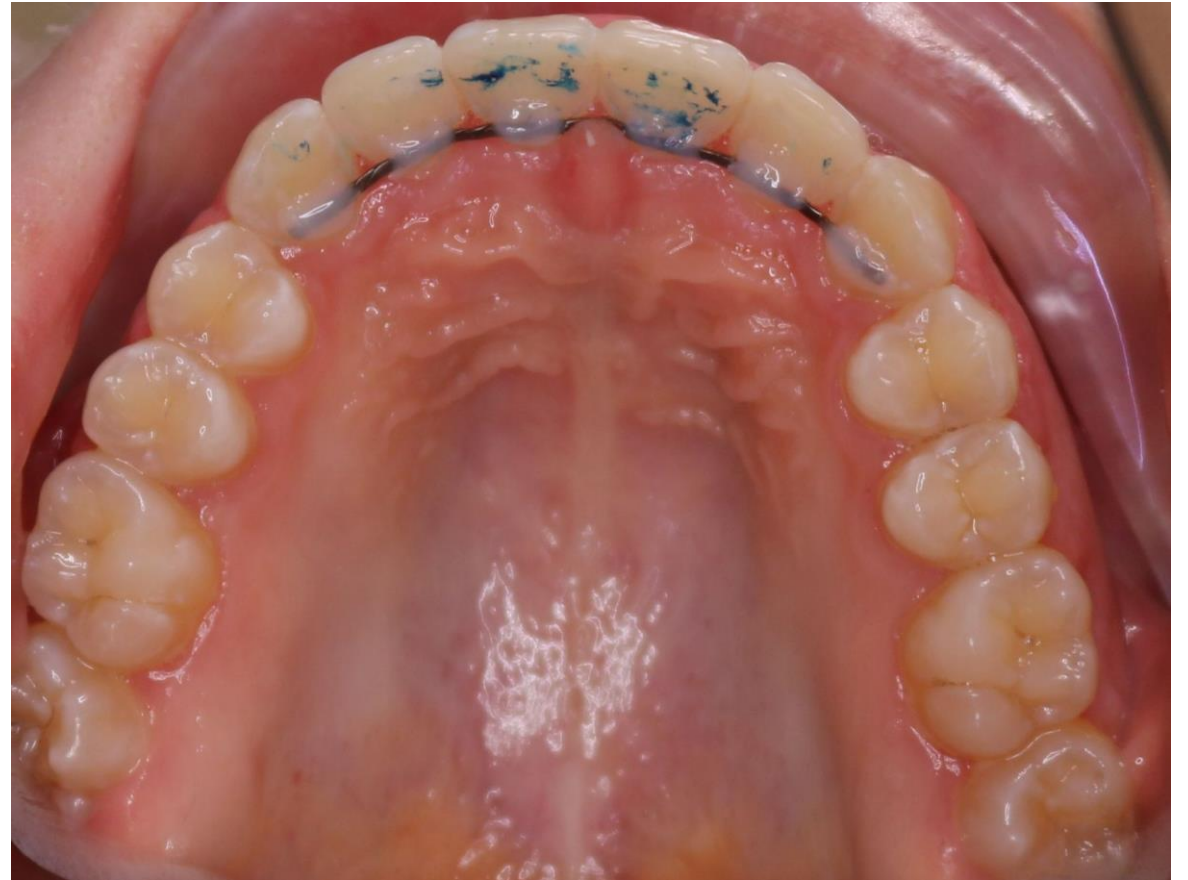



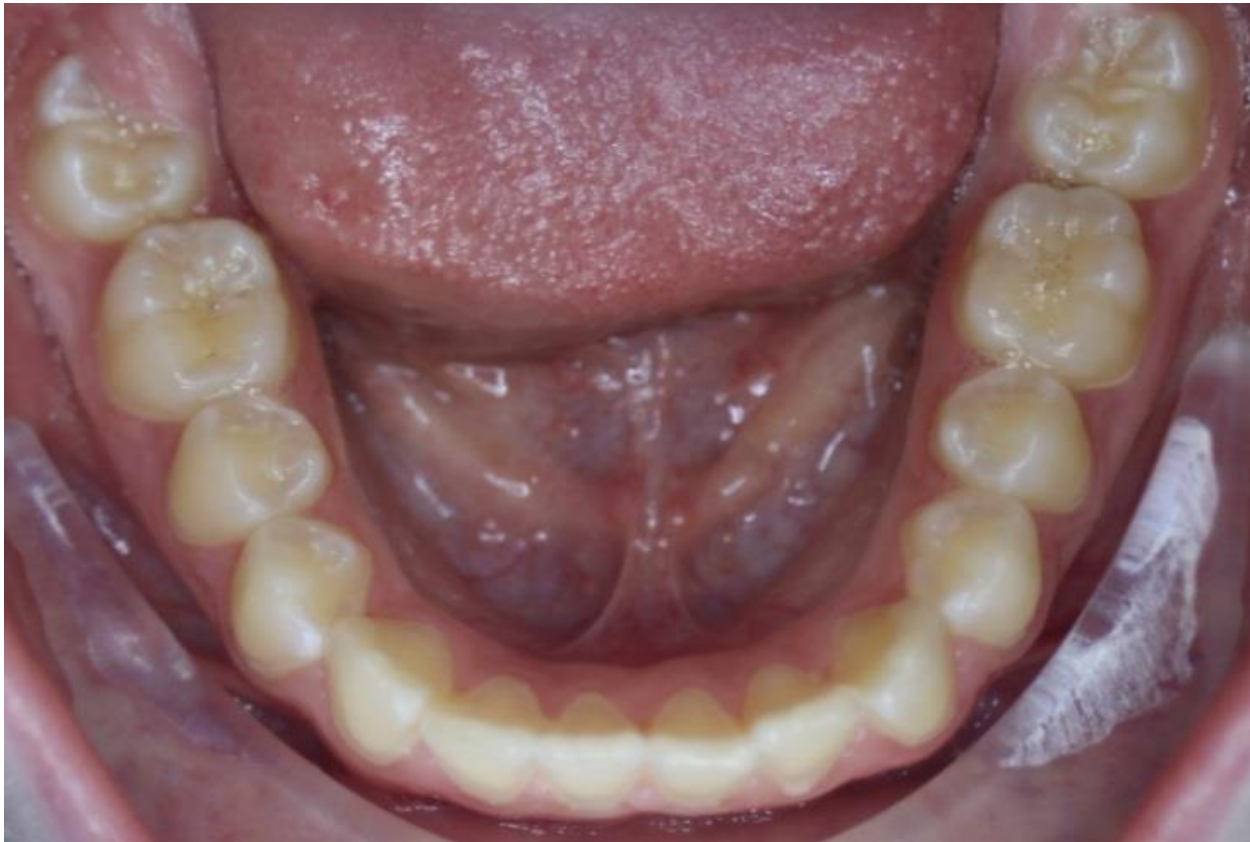Before



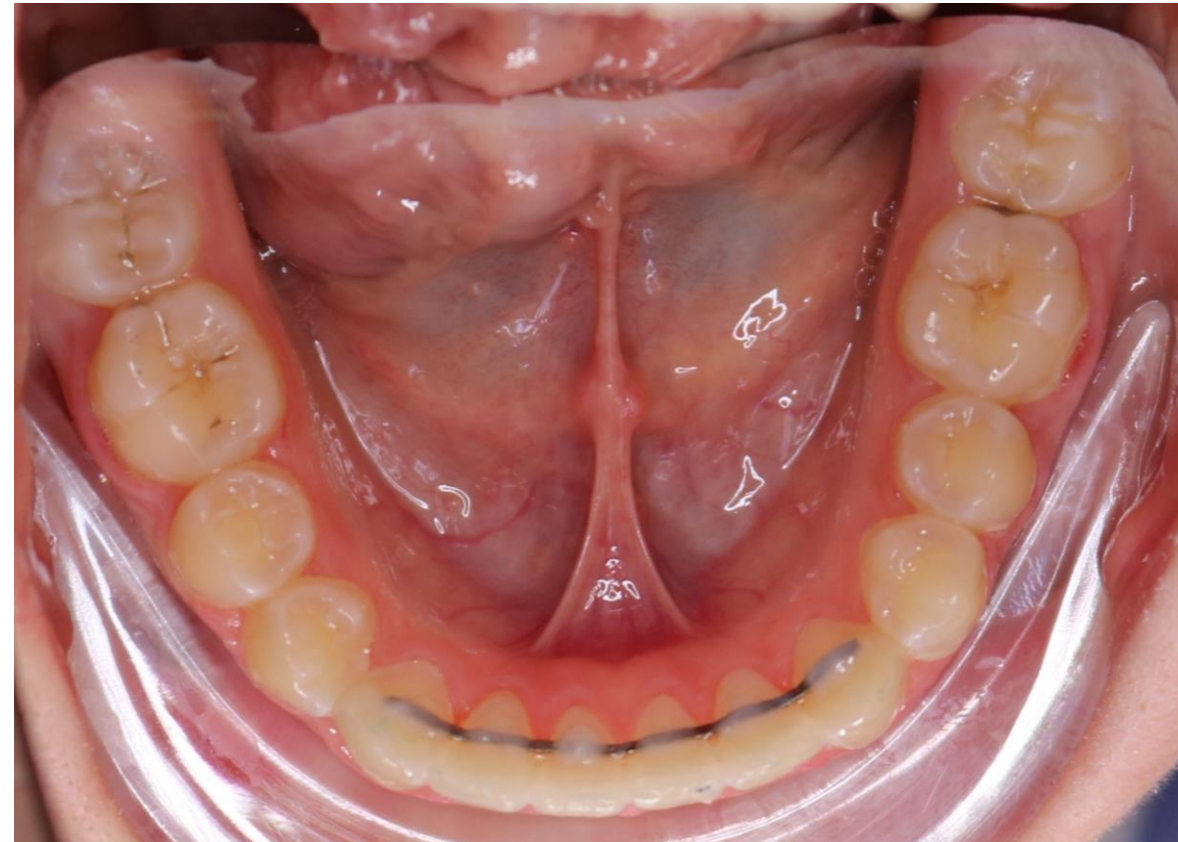
After



Before

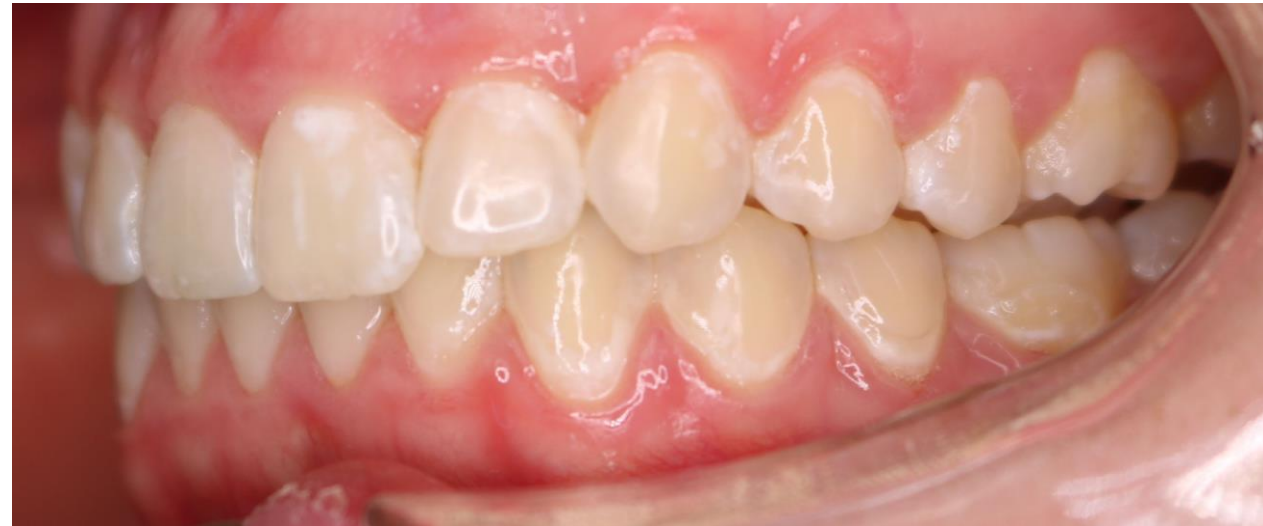
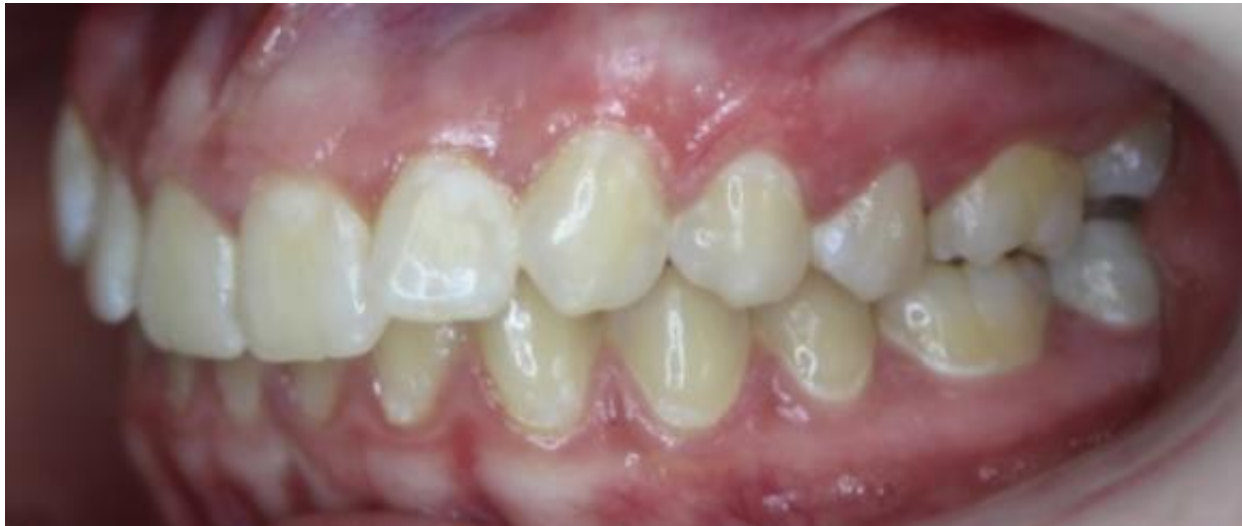
After



Before

After



Before

After

