



# eXceed Aligners Case Presentation

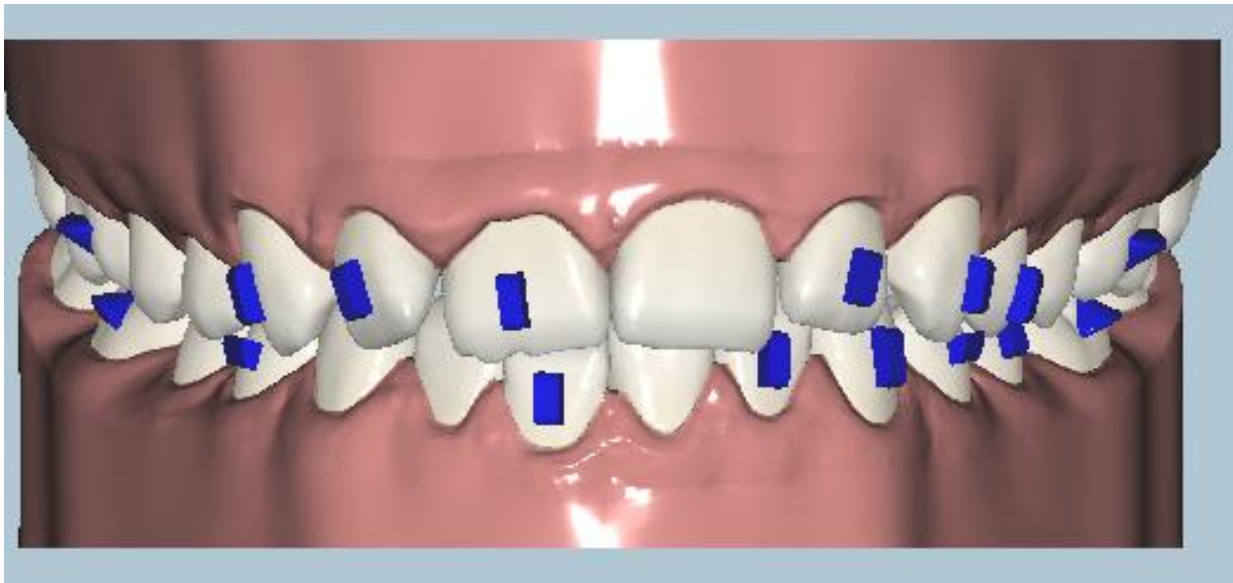
December 15, 2020

Courtesy of Dr. Dr. Artem Kuznetcov

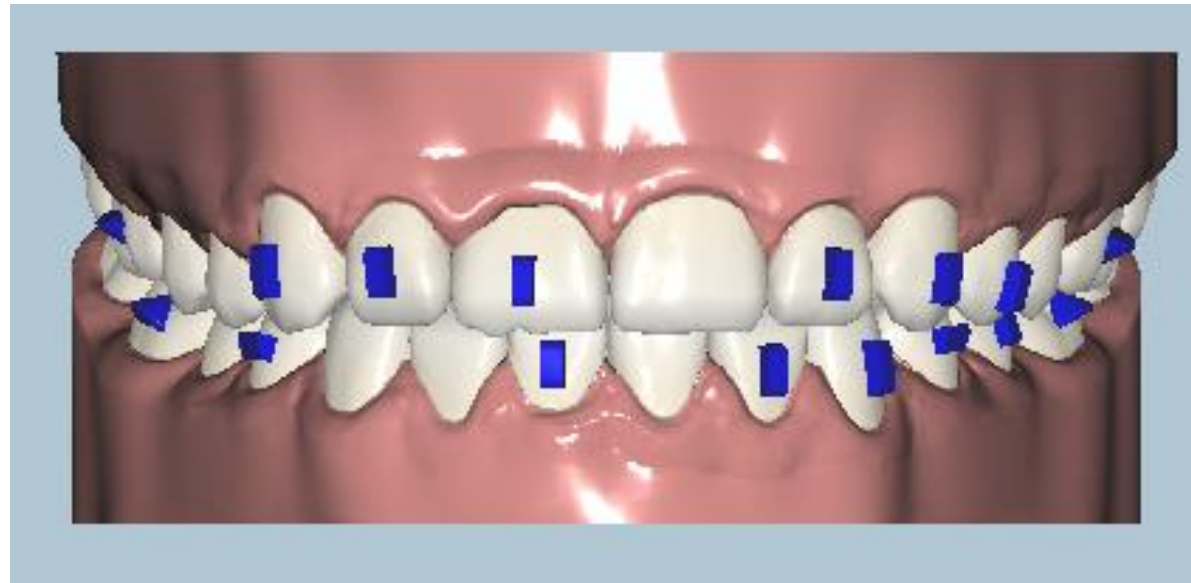
## Case Details

- Patient details: Male, 15 years old
- Chief patient complaints: Aesthetics
- Treatment plan: Resolve anterior crowding and improve torque and angulations
- Aligners: upper – 26 aligners , lower – 14 aligners
- Start date: November 2019
- Finish date: December 2020
- Treatment time: 13 months.

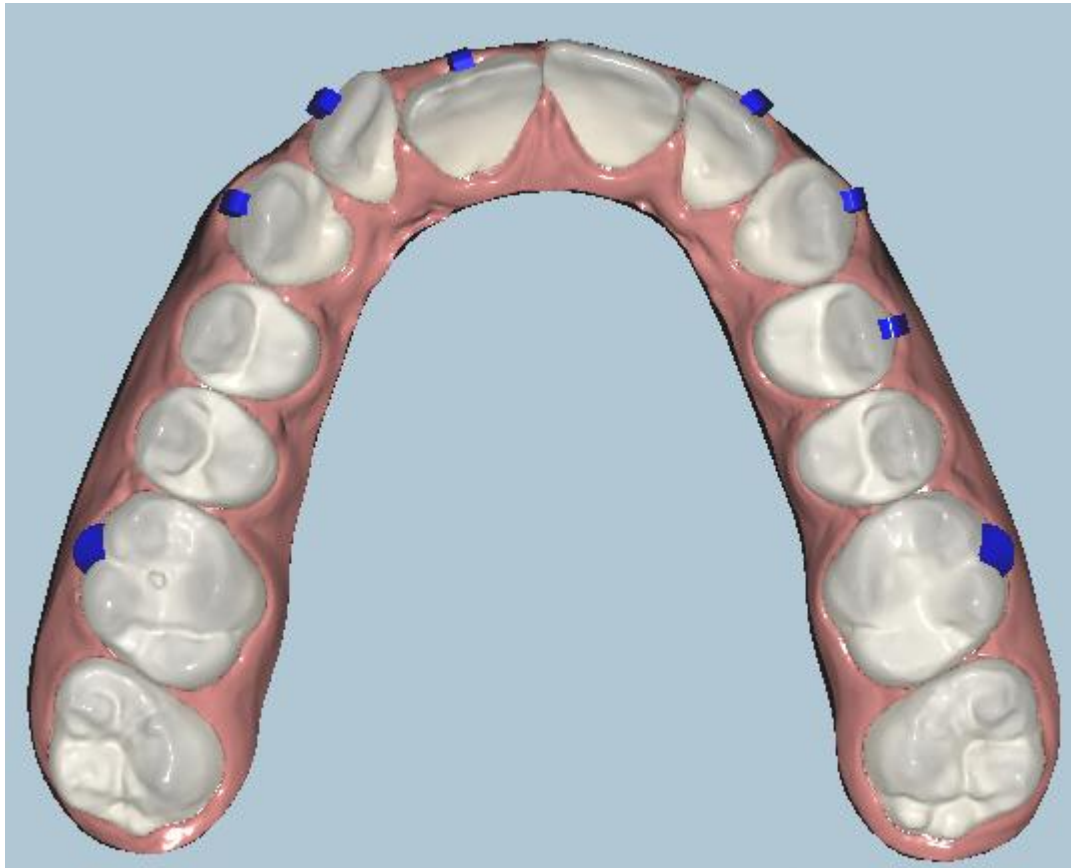
Before



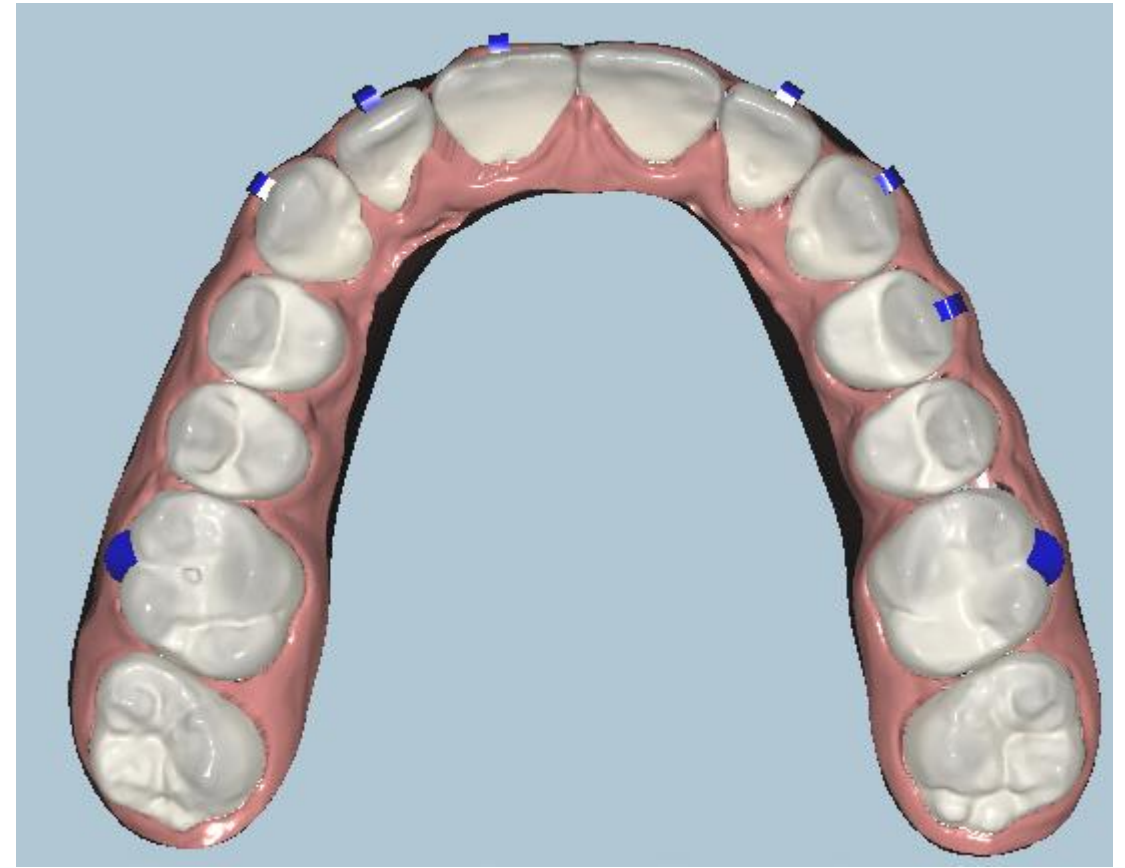
After



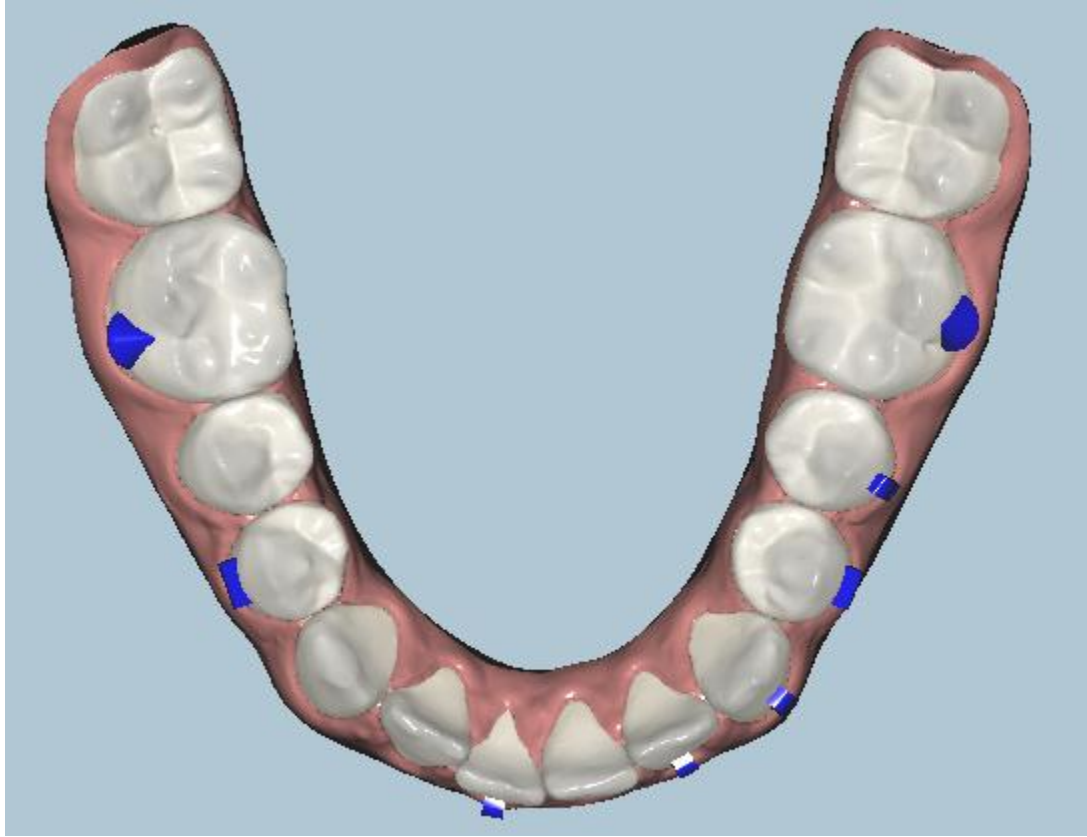Before



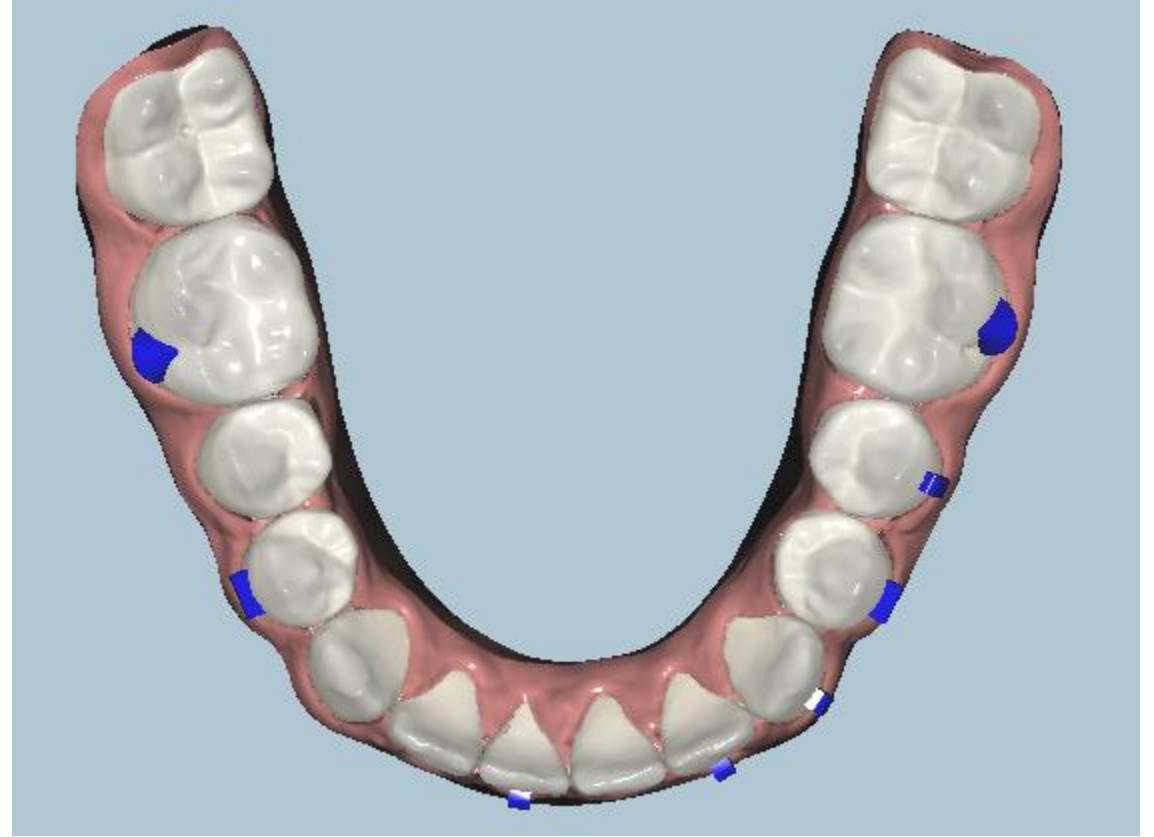
After



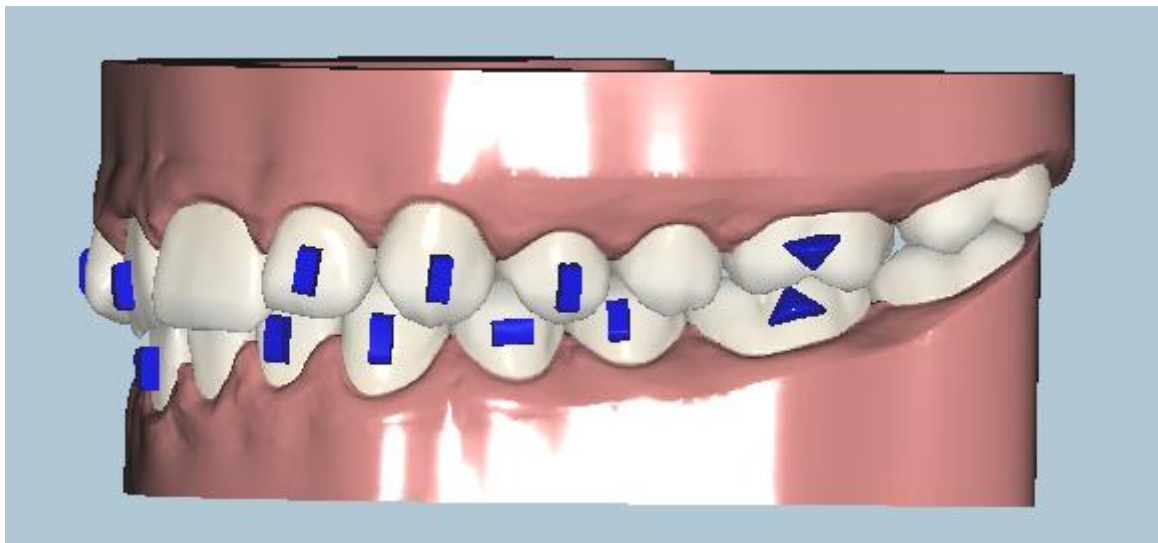
Before



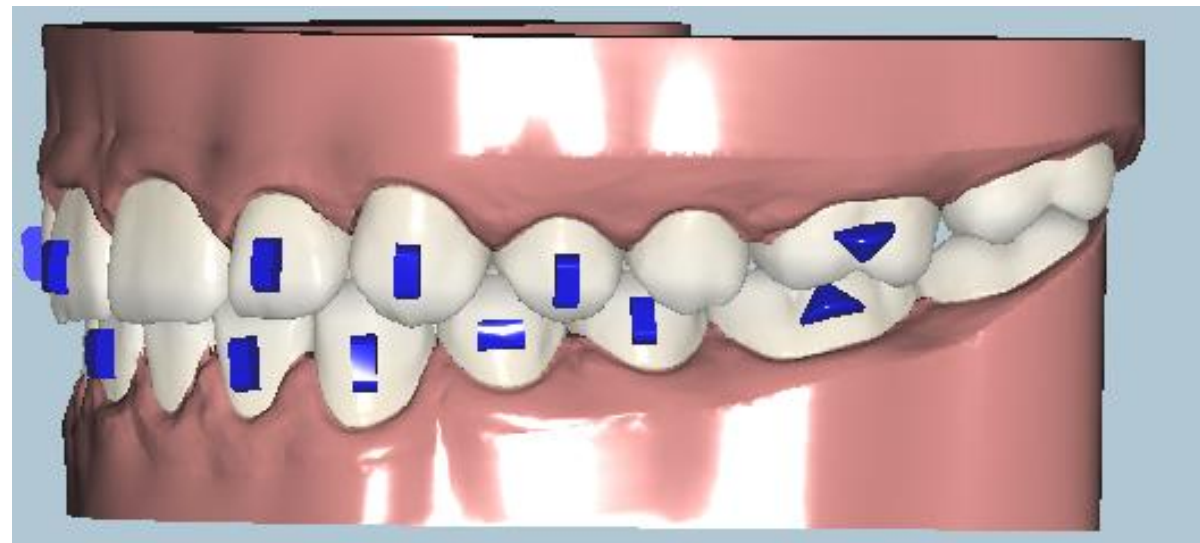
After



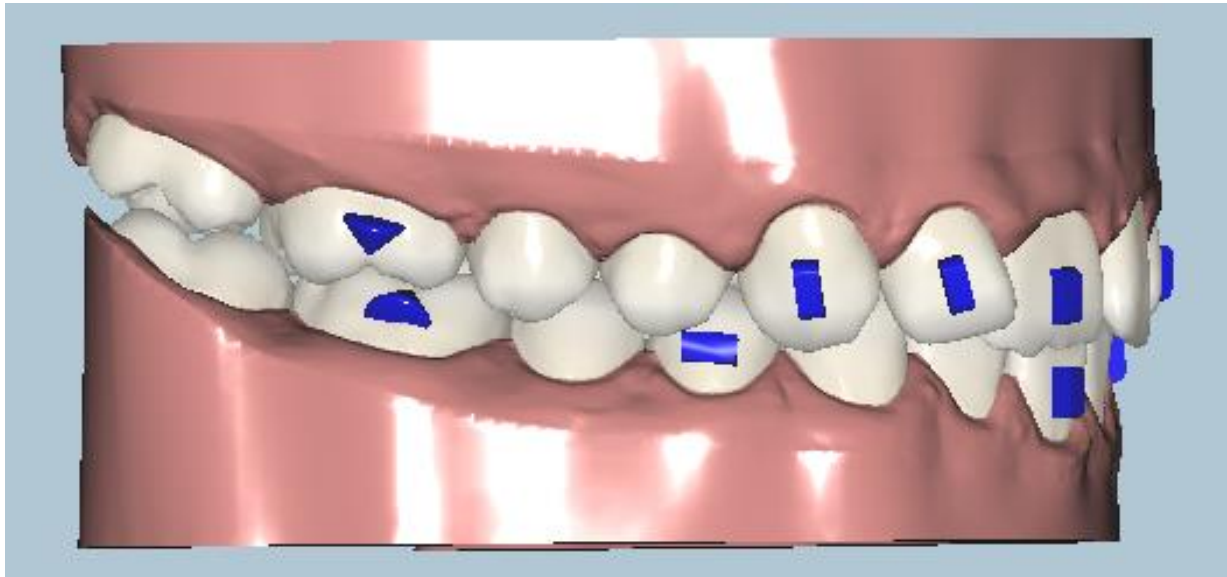
Before



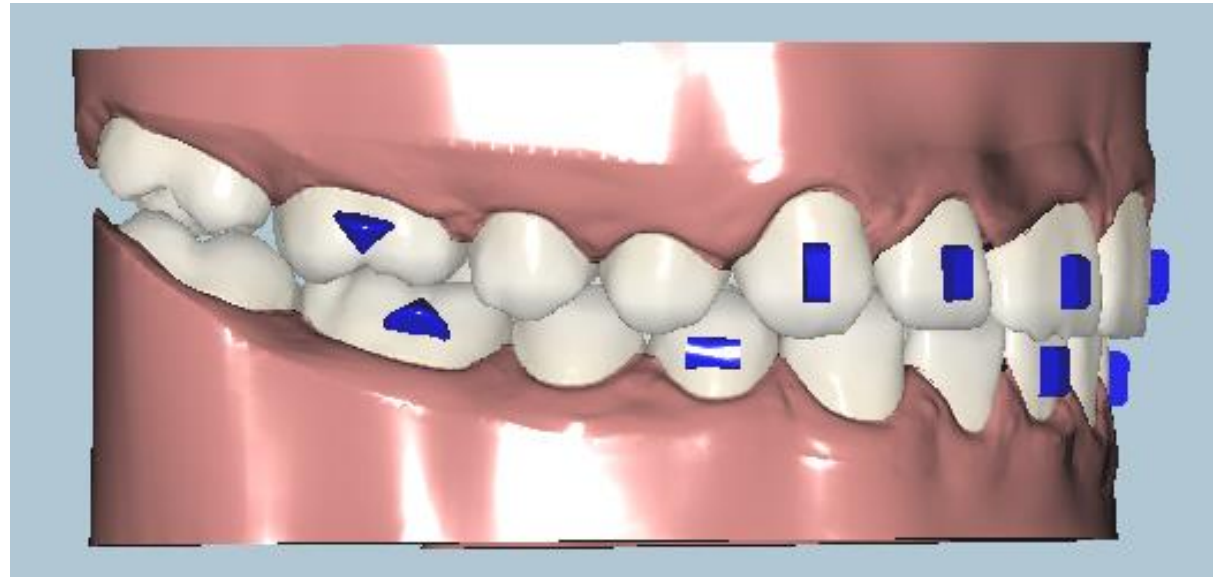
After



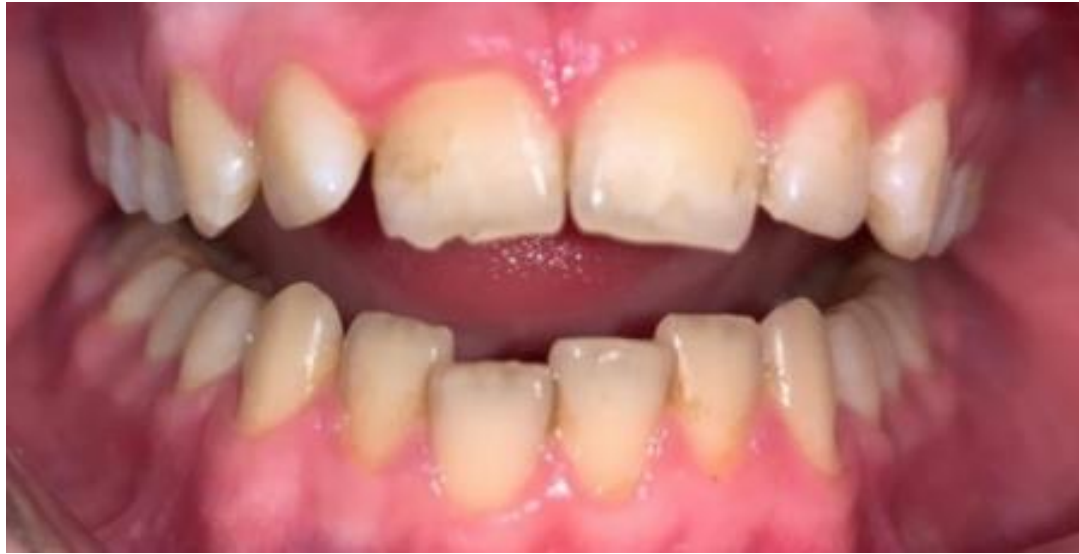Before



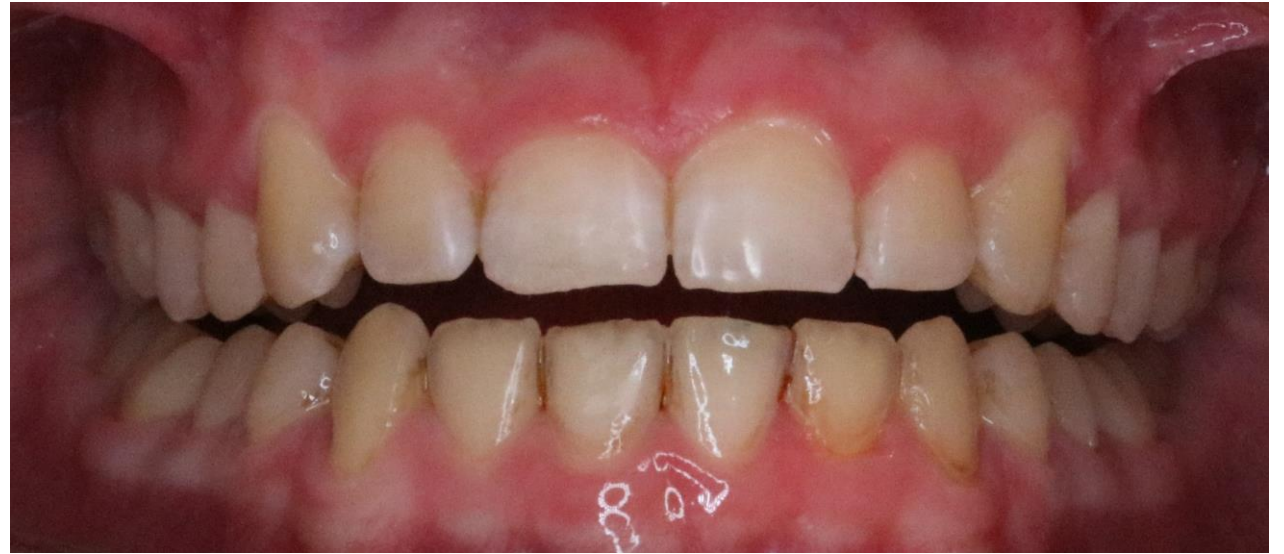After



Before

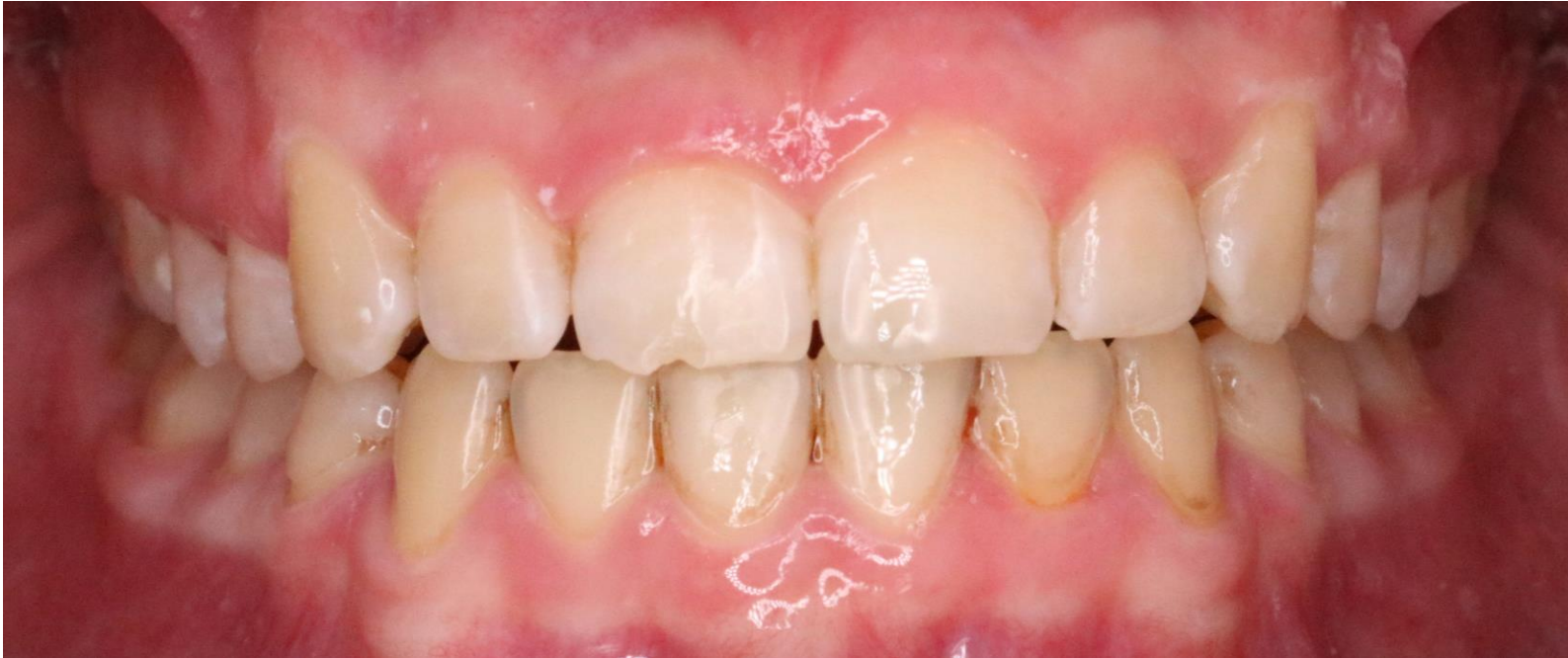

After

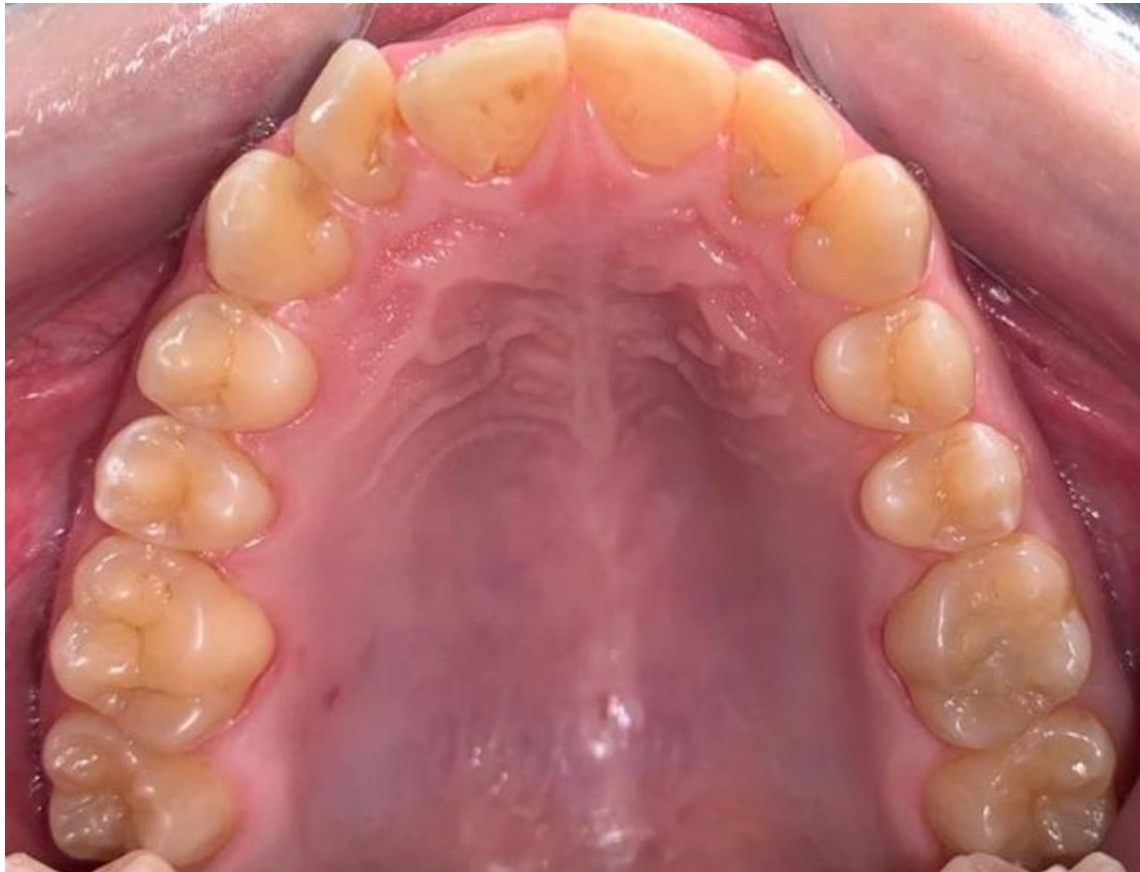



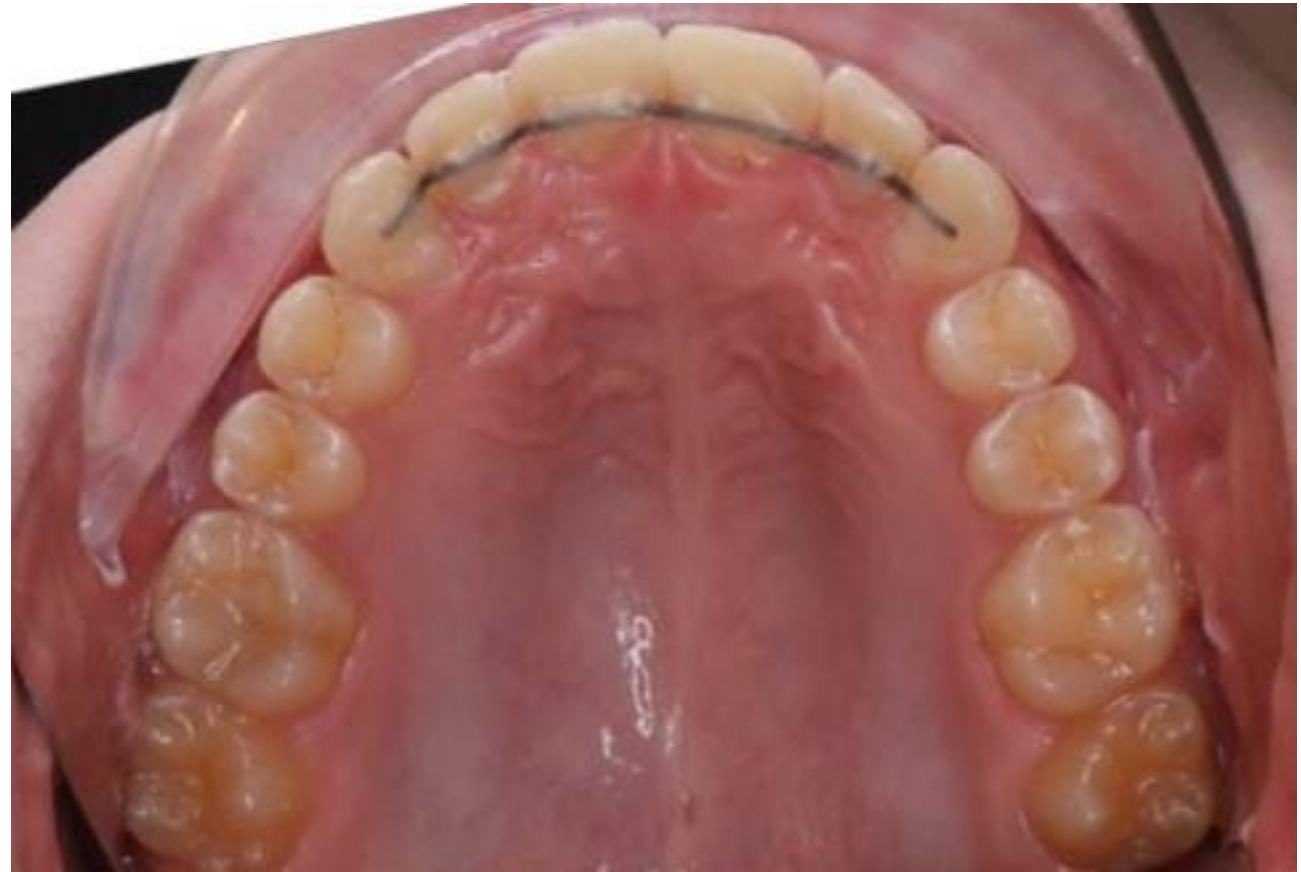After



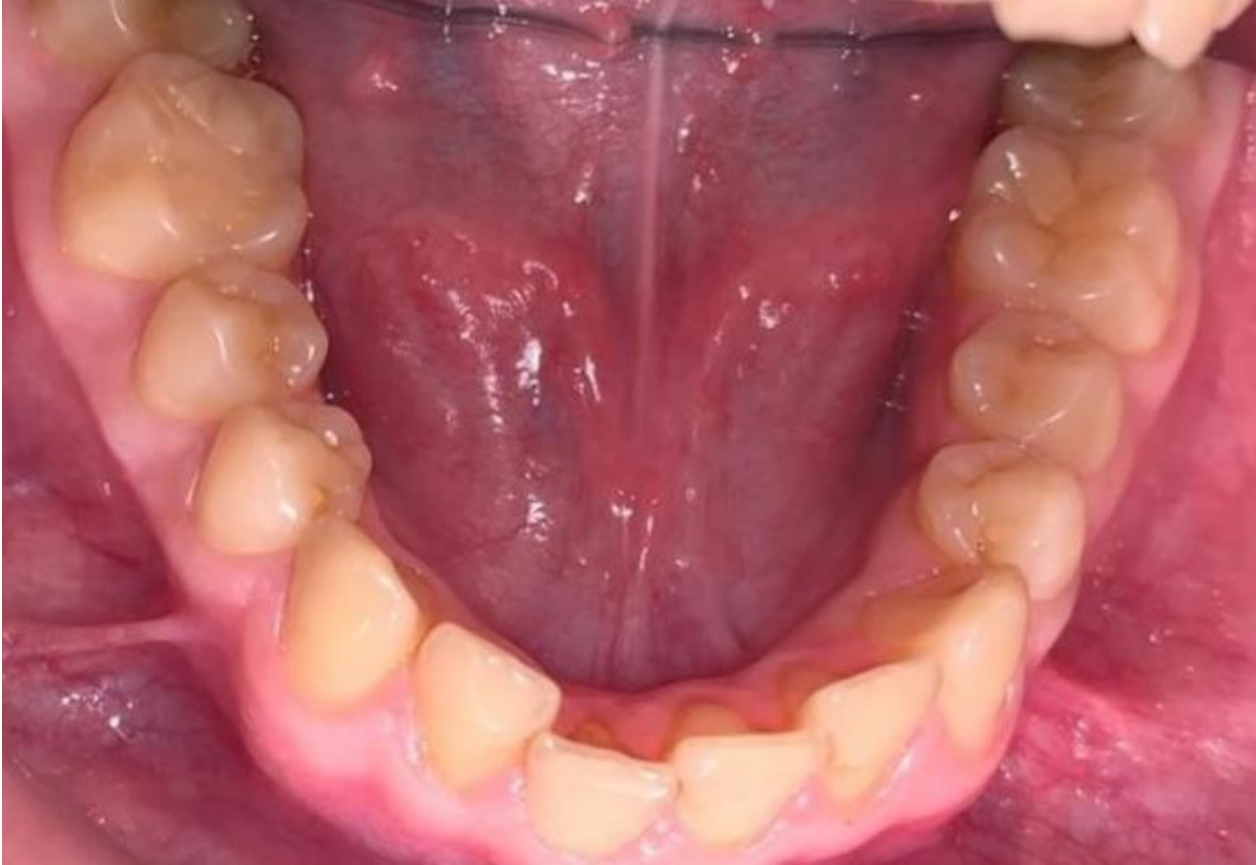Before



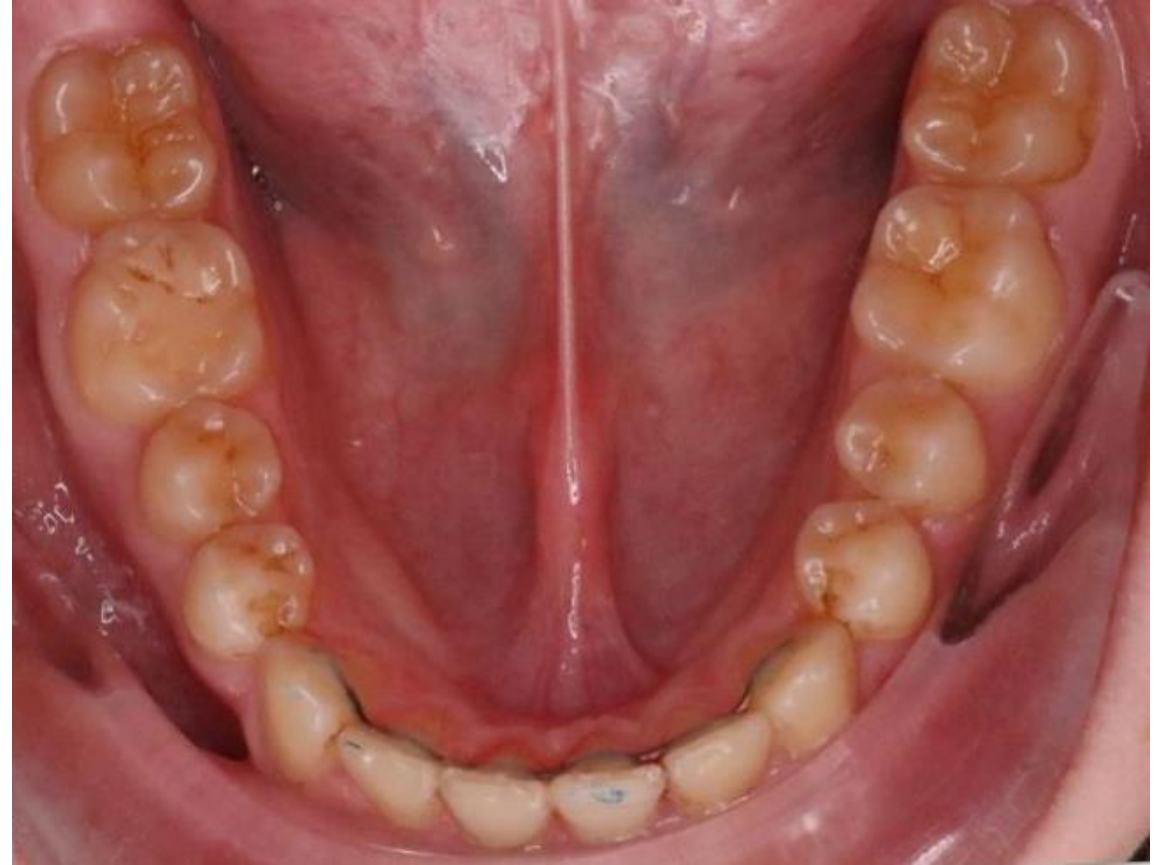After



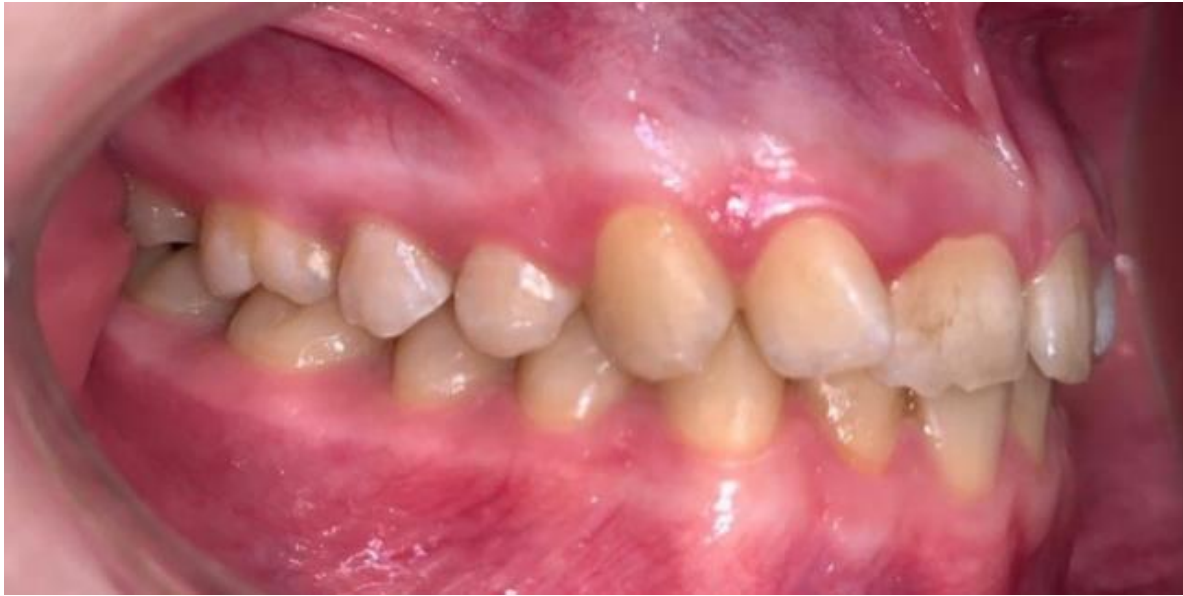Before



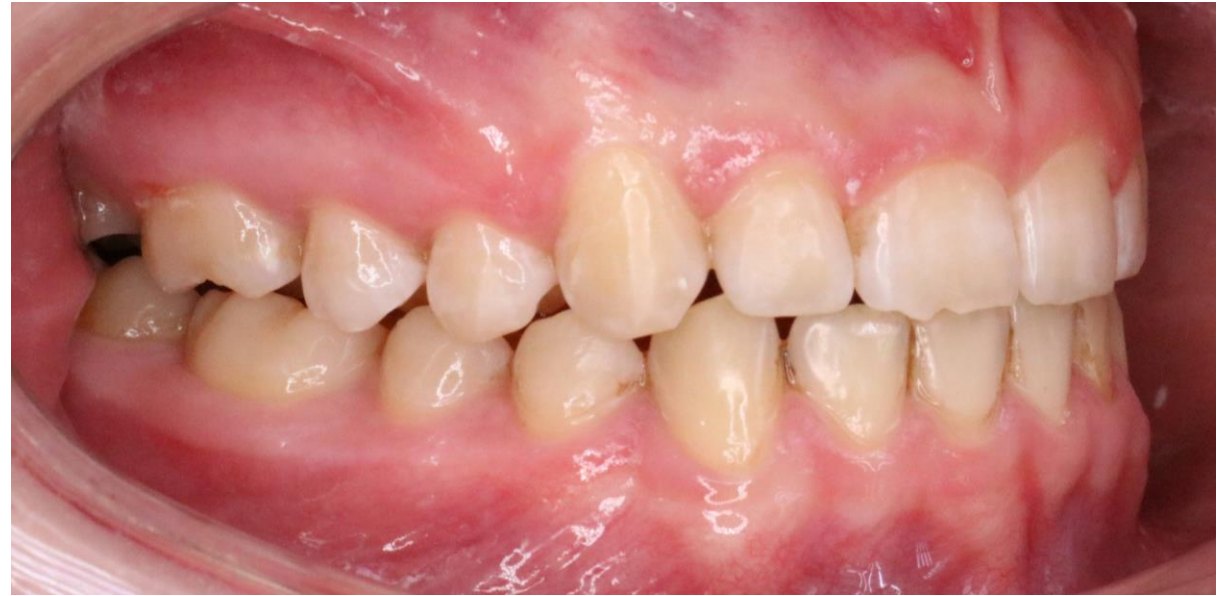After



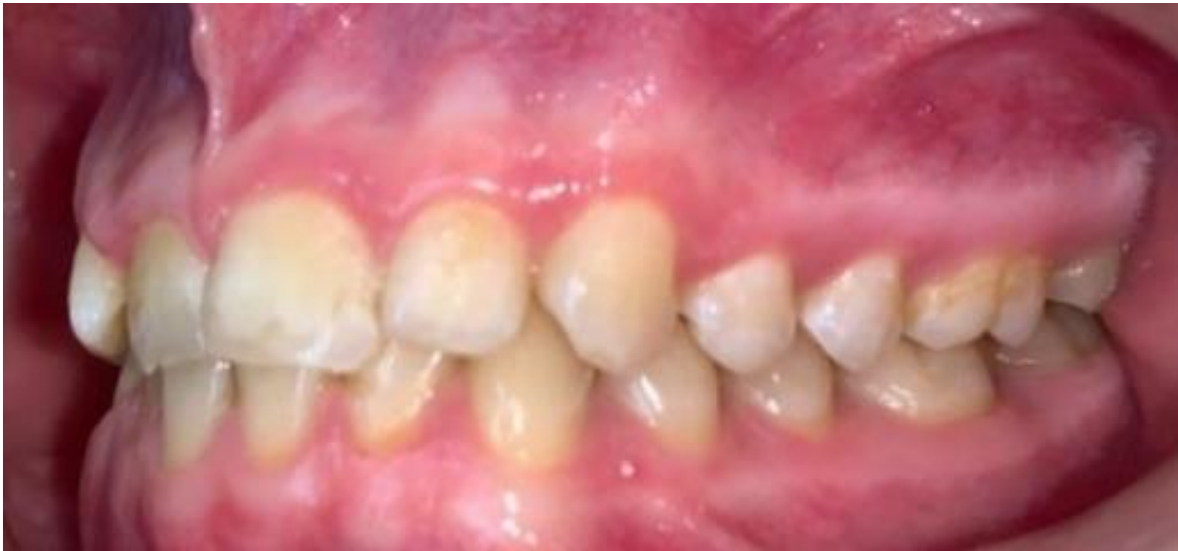Before



After



Before



After

