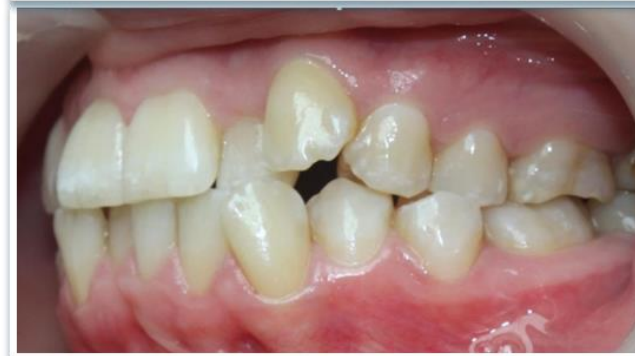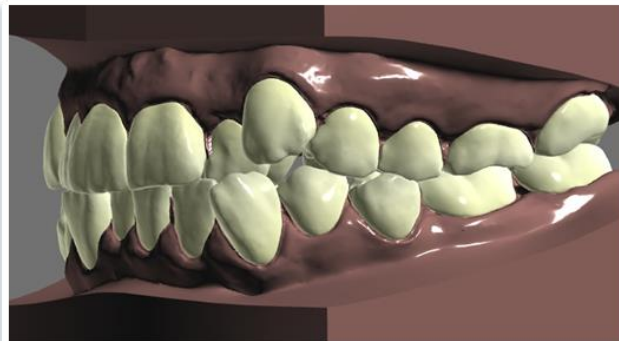
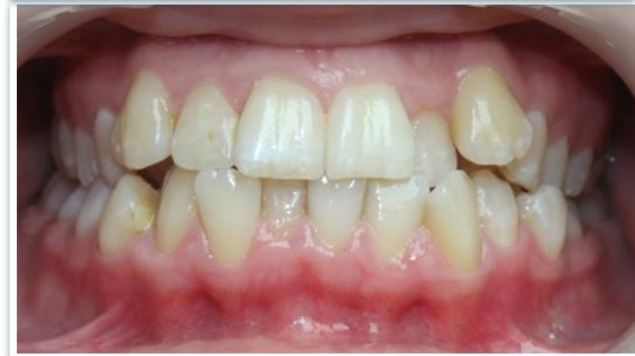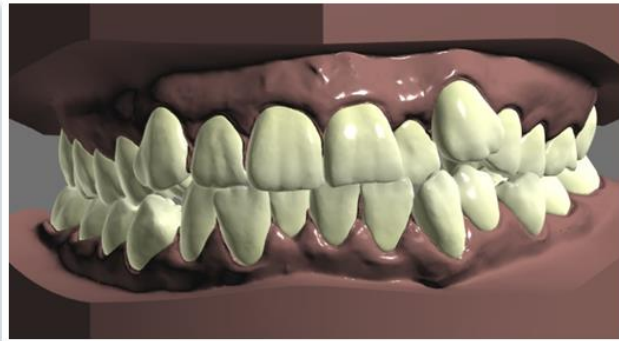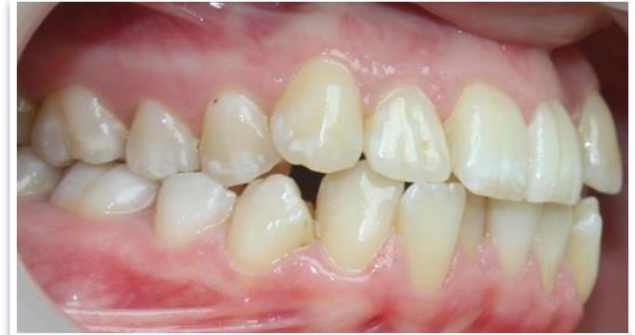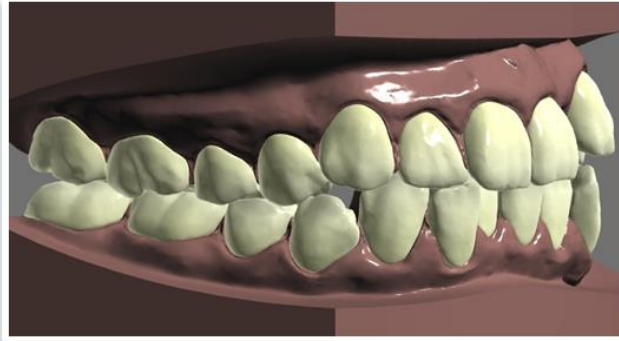




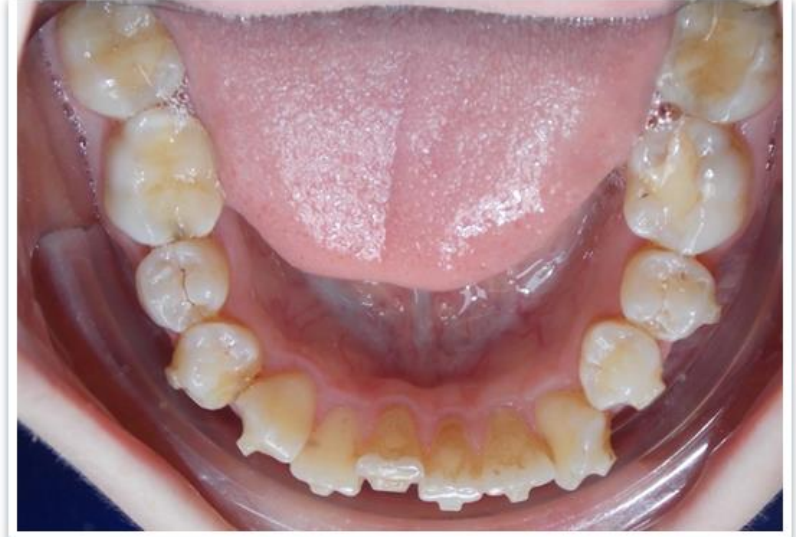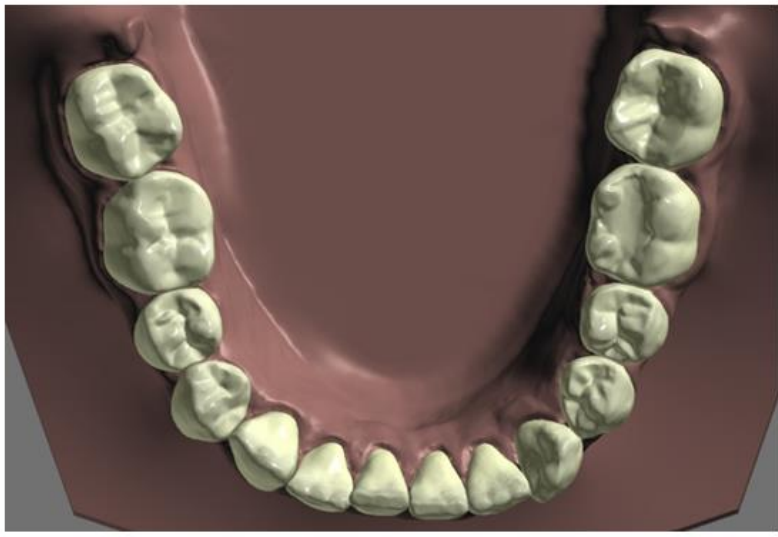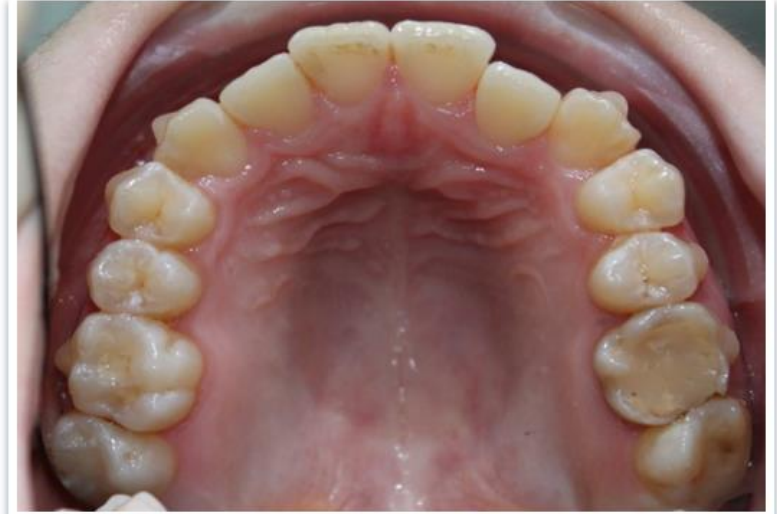
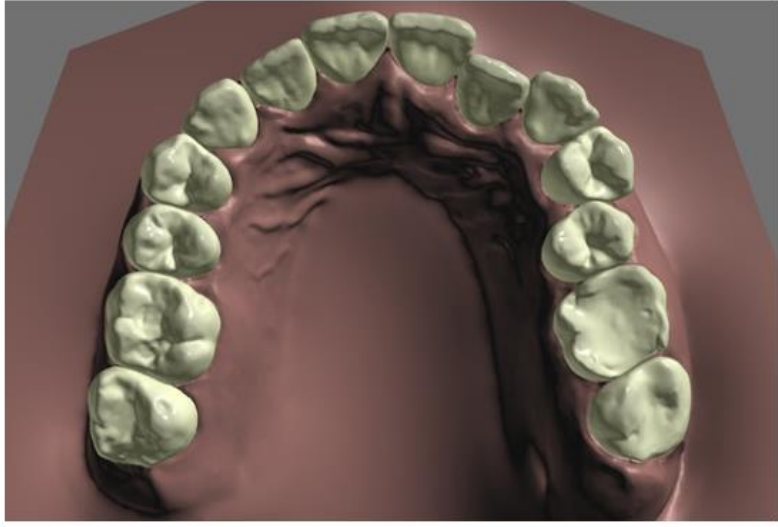
eXceed Aligners Case Presentation

August 21, 2016

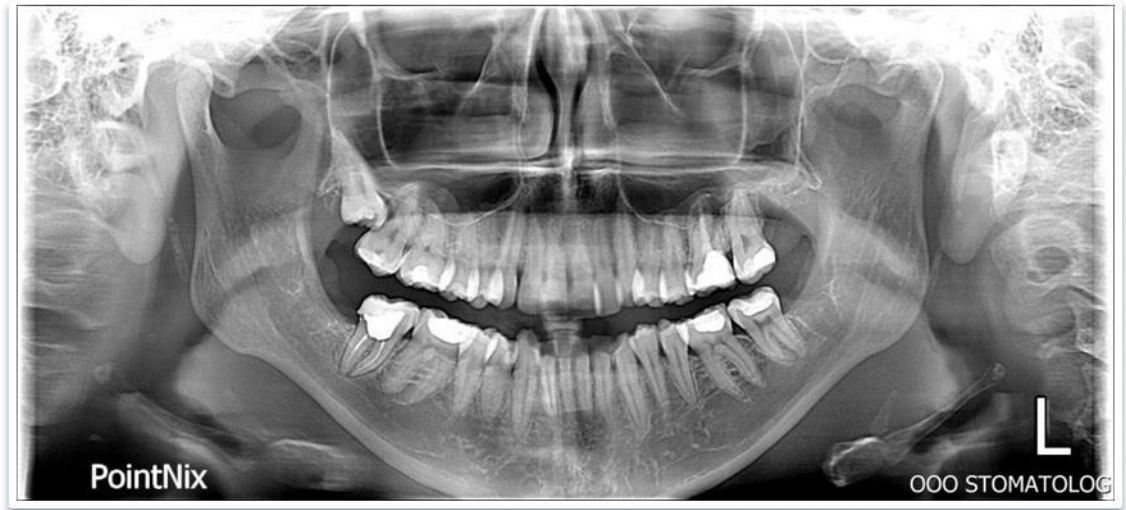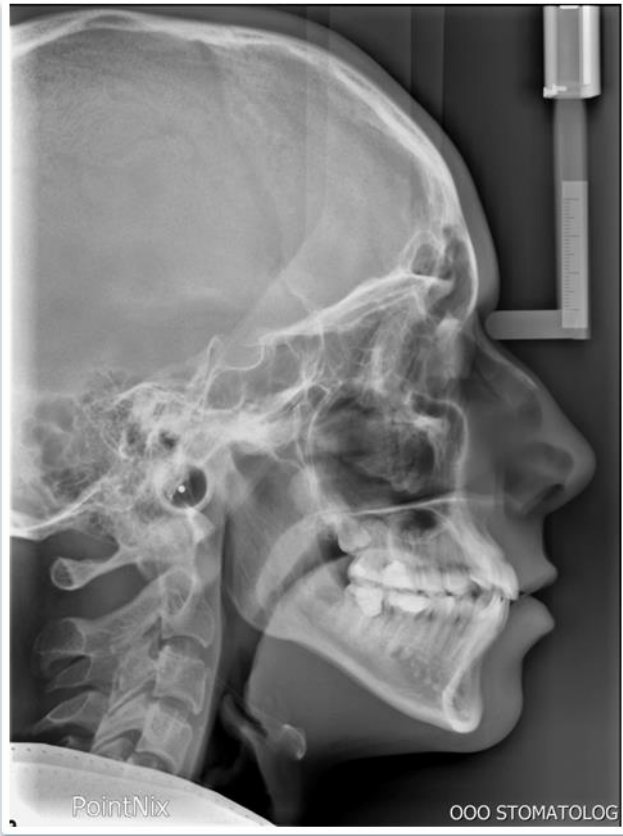Pre-Treatment 3D models and intra-oral images



Pre-Treatment – Occlusal View



Pre-Treatment Lateral Ceph and Panorex



Case Details

Patient details: Female, 25 years old

Patient chief complaints: “Crooked upper and lower teeth”

Diagnosis: Skeltal class I, (Class III tendency), Dental Class I mild-moderate crowding. Minimal Overjet and Overbite. Upper midline 1 mm to Left. Lower midline 1mm to Right. Cross bite 14,22,25. Palataly positioned 22. 12/42 Tete-a-Tete. Blocked out-high 23, Rotated 33. Mesially inclined, impacted 18. Good oral hygiene and healthy gums.

Treatment plan: eXceed aligners with attachments; Level and align; Expand upper arch; Interproximal reduction upper and lower teeth; Bonded Retention wires upper and lower.

Aligners: upper arch – 36, lower arch – 23

Start date: 12.03.2014

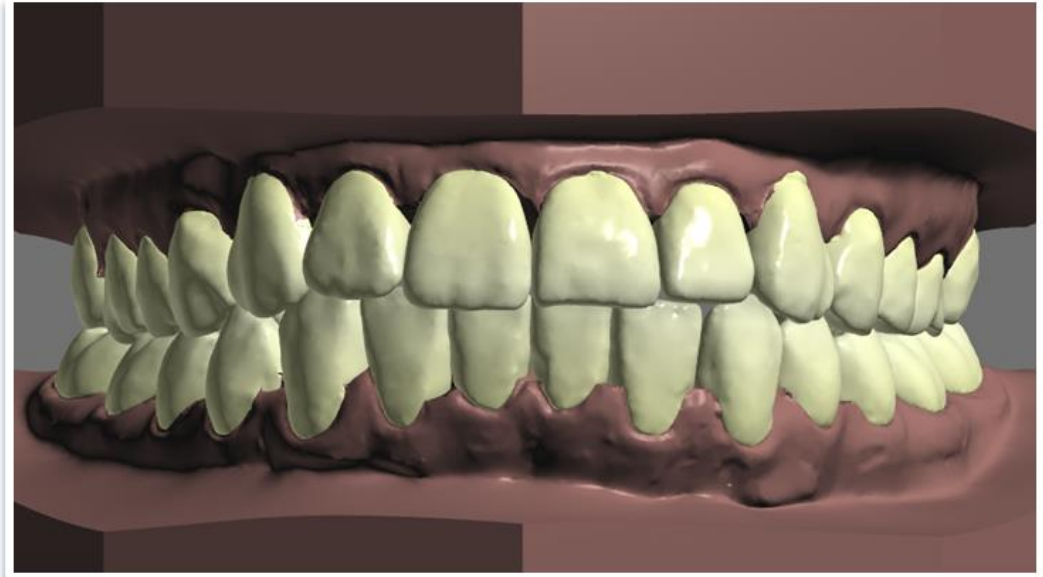
Mid-Course correction: yes, due to tooth 23 extrusion. Aligners for stages 10-11 were re-manufactured.

Finish date: 27.11.2015

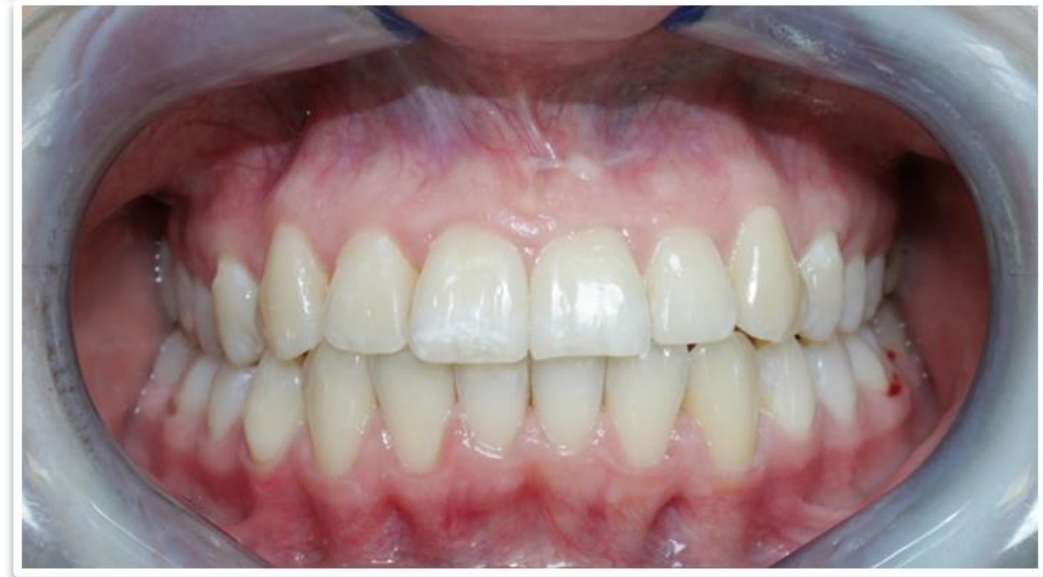Actual treatment time: 20 months

Post Treatment – Frontal View

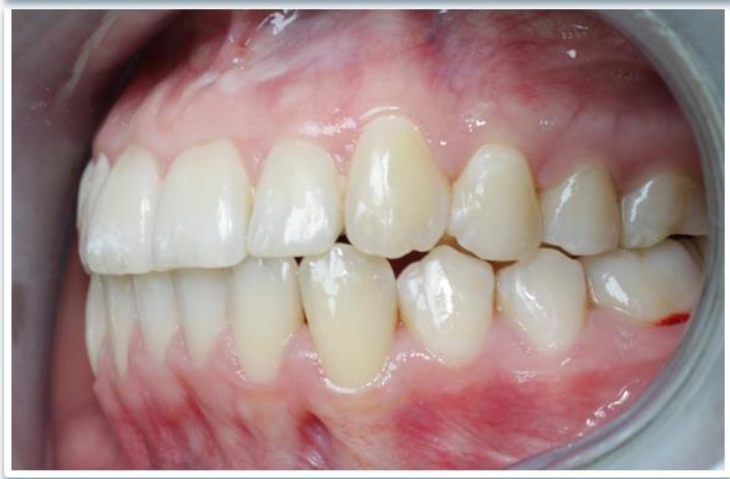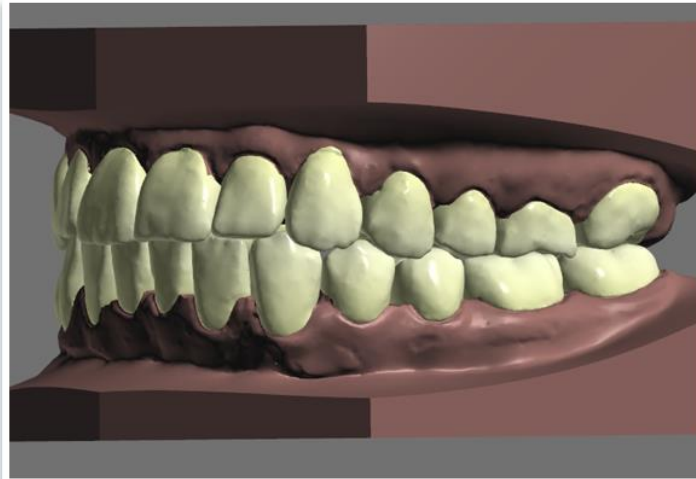
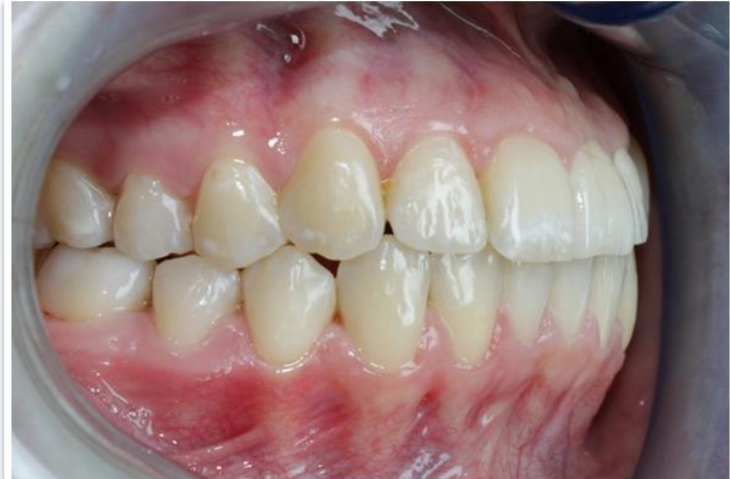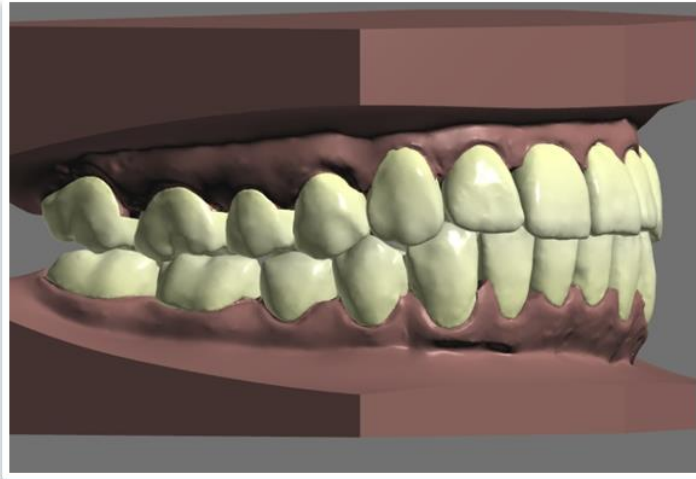
Virtual Outcome –
03.2014



Actual Outcome –
11.2015



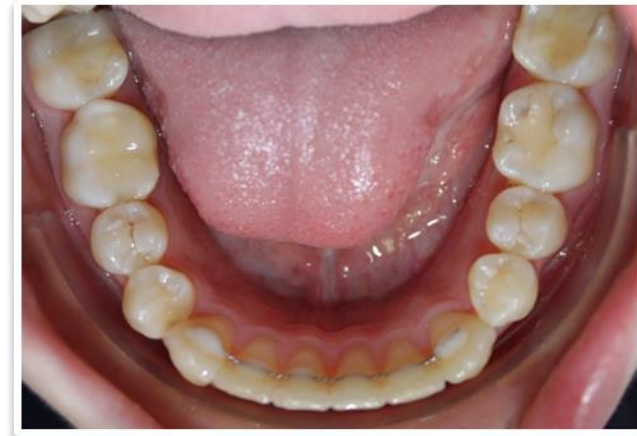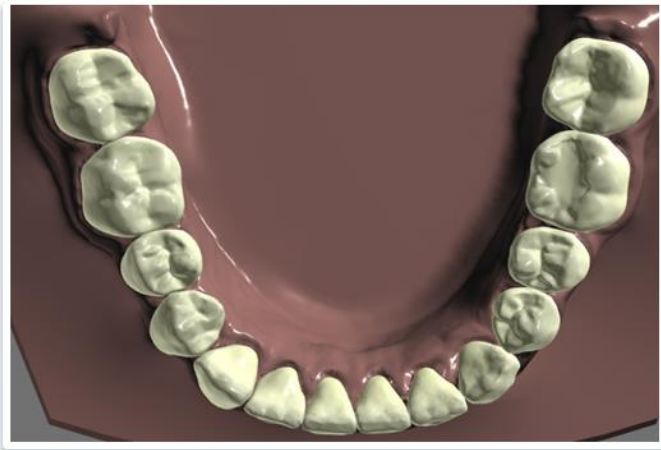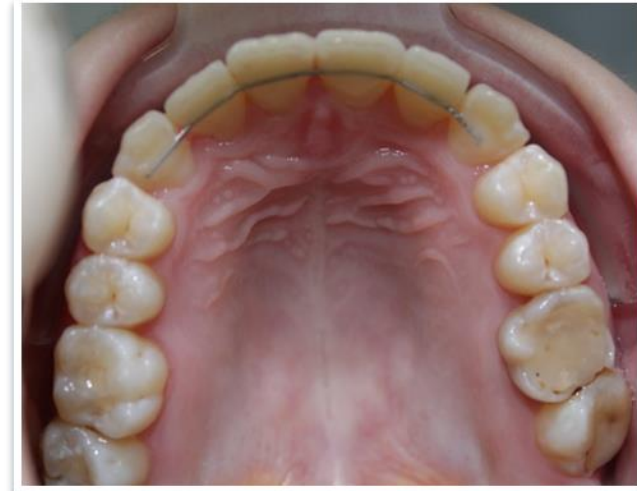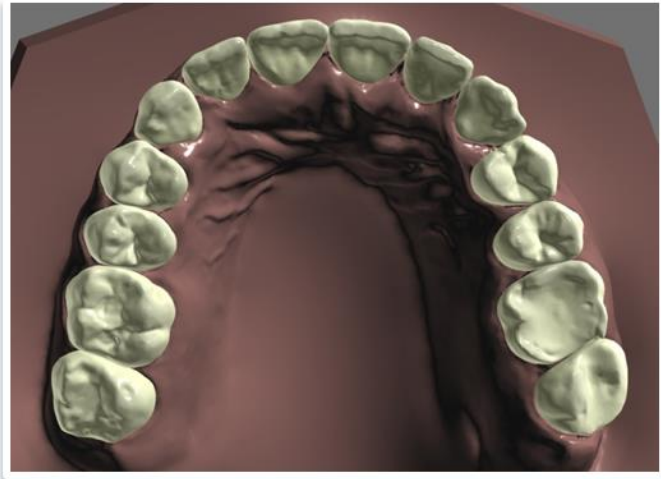
Post Treatment – Side View



Virtual Outcome – 03.2014

Actual Outcome – 11.2015

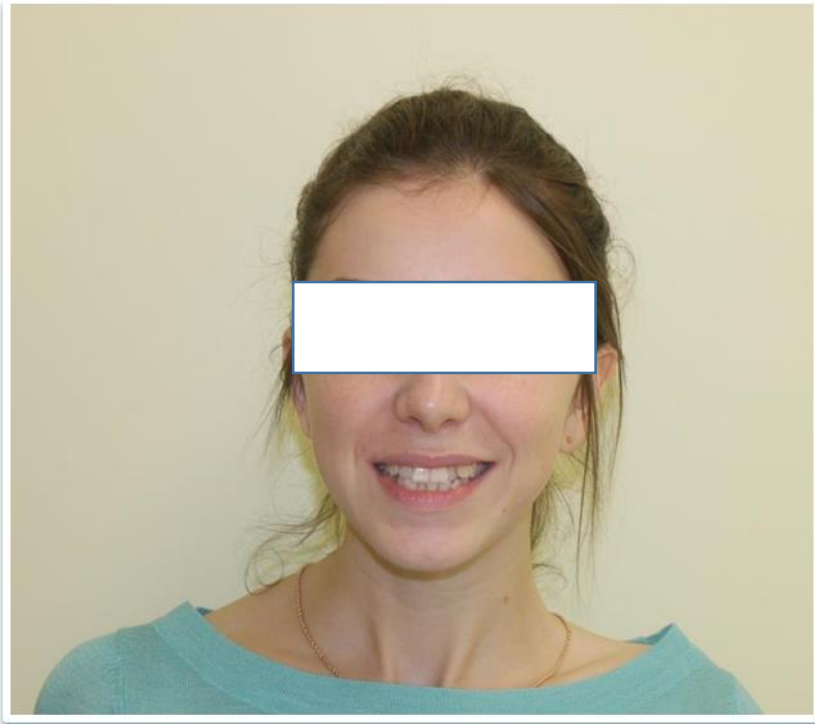Post Treatment – Occlusal View



Virtual Outcome – 03.2014

Actual Outcome – 11.2015

Pre and Post Treatment Facials



Pre-Treatment



Post-Treatment