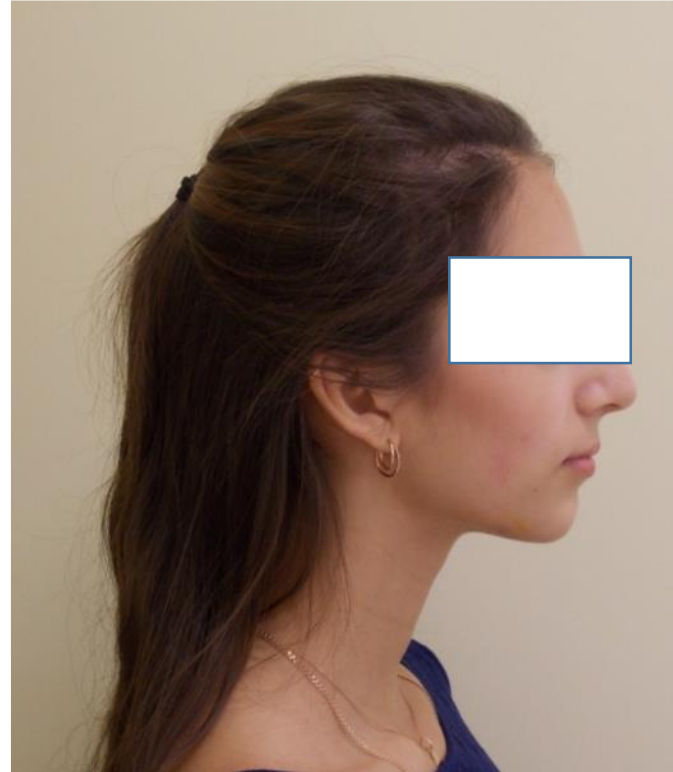



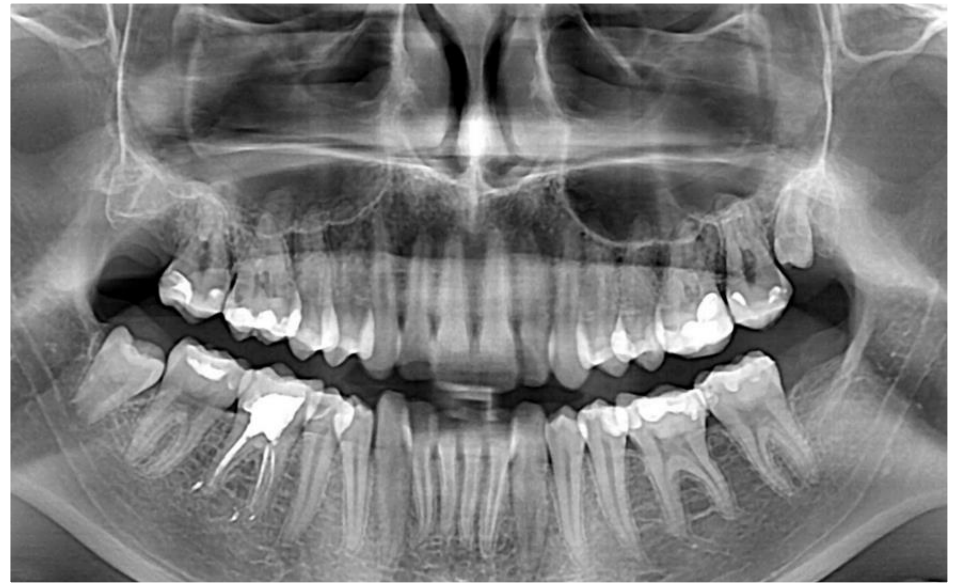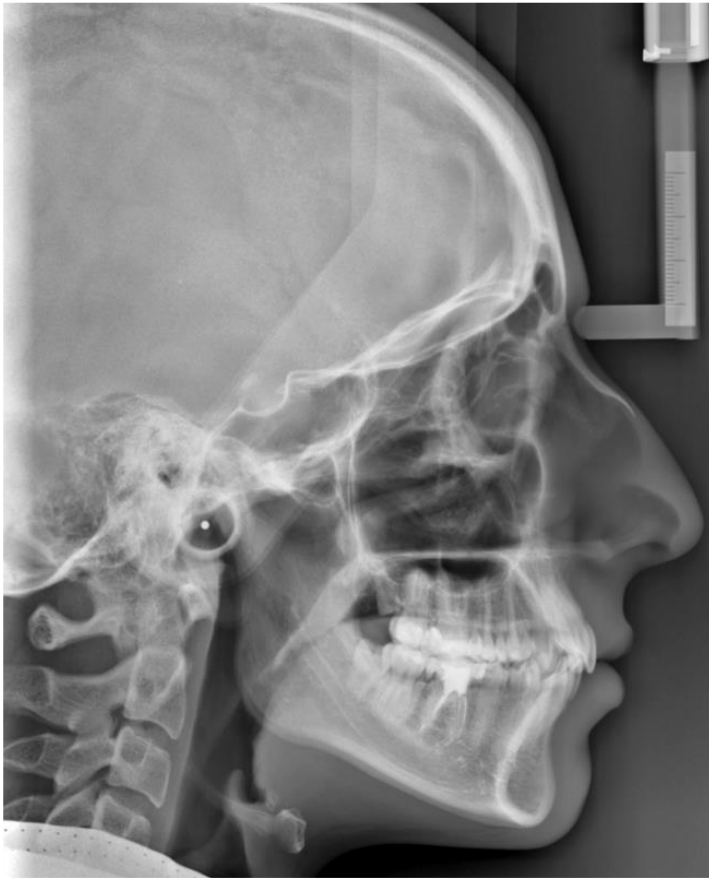eXceed Aligners Case Presentation

April 12, 2016

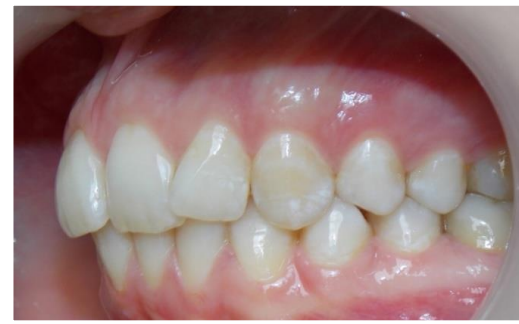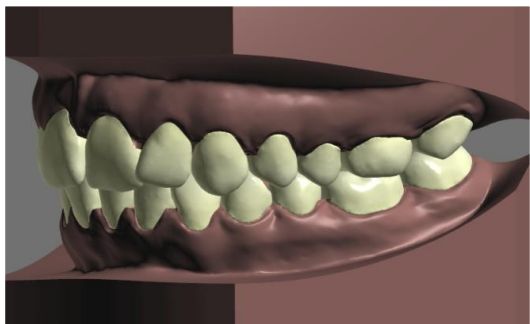
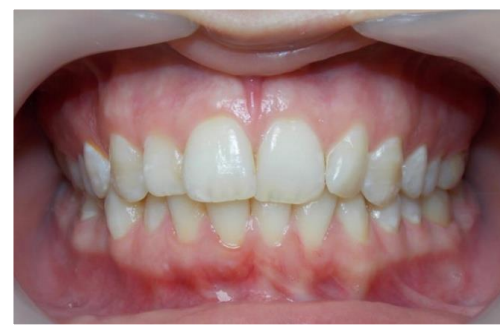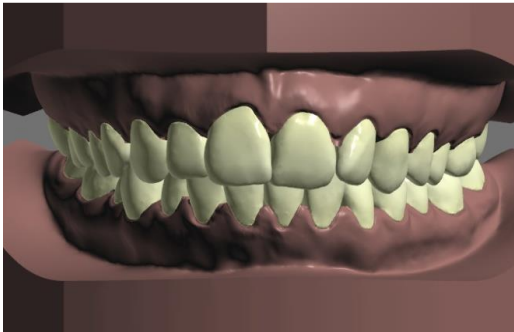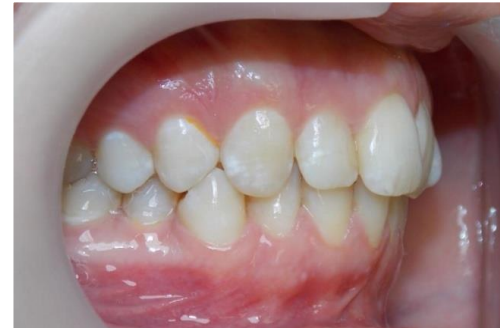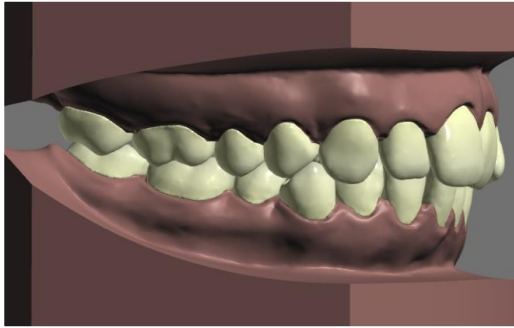
Pre-Treatment Records – facials



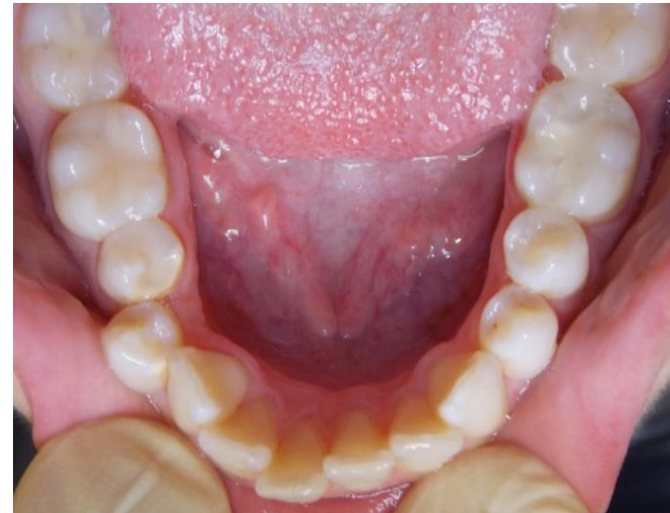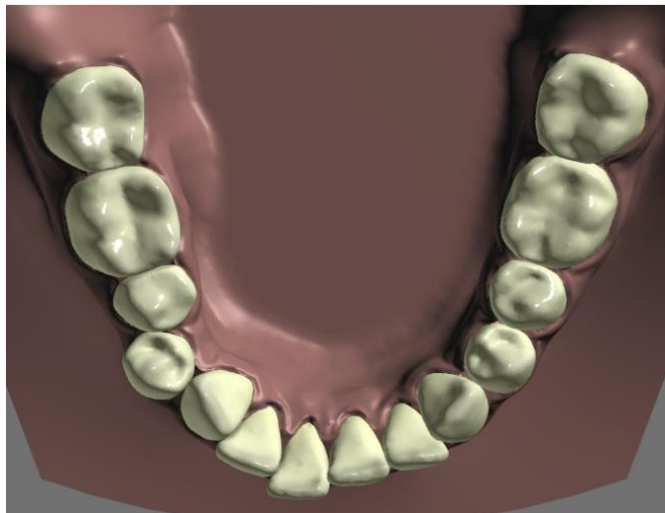
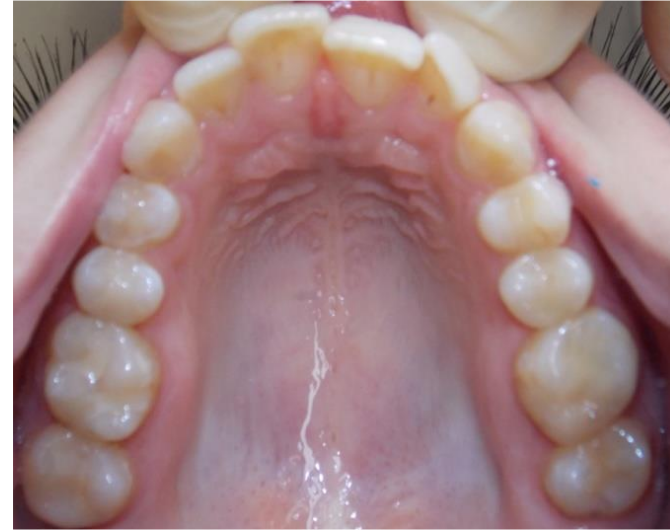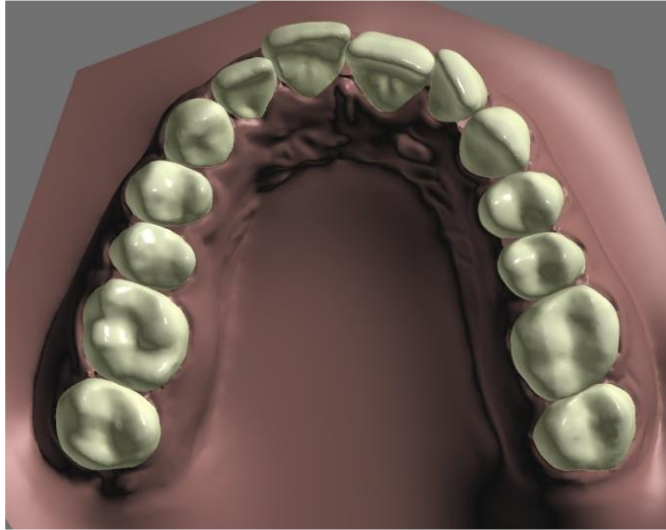
Pre-Treatment Records – X-rays



Pre-Treatment Records – Intra-orals



Pre-Treatment Records – Occlusal



Case Details

Patient details: Female, 20 years old

Chief complaints: improve teeth position and smile

Diagnosis: dystopia and inclinations of individual teeth, anterior crowding

Treatment plan: extract 8th, level and align, alleviate crowding.

Aligners: upper arch - 13, lower arch - 15

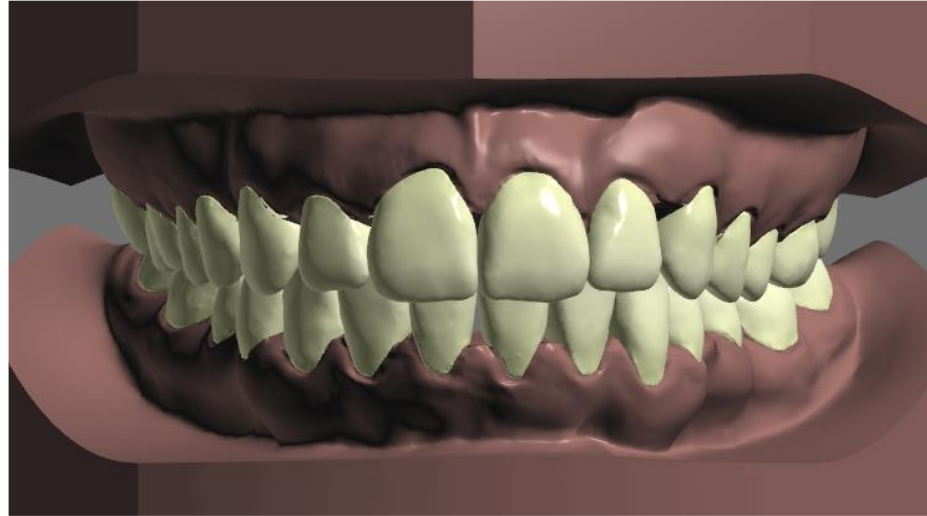
Start date: July 07, 2015

Finish date: Feb. 26, 2016

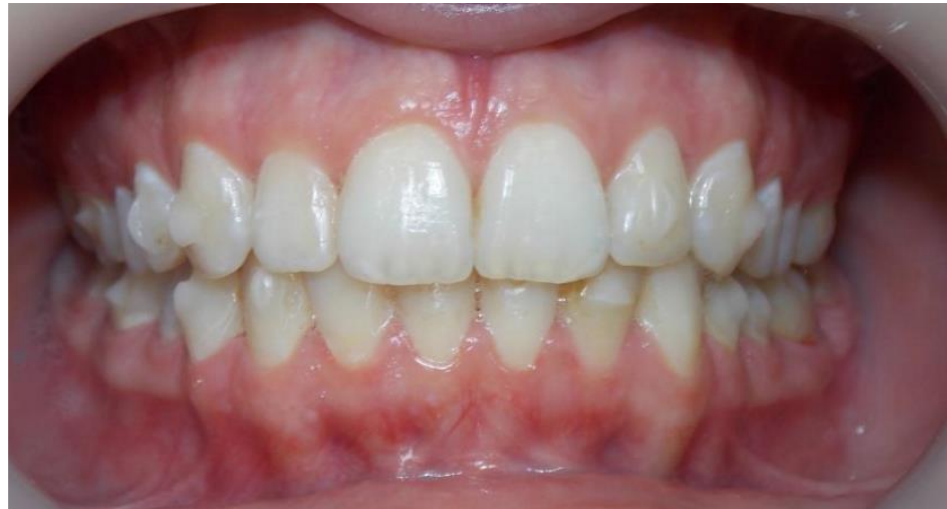Actual treatment time: 7.5 months.

Post Treatment – Frontal View

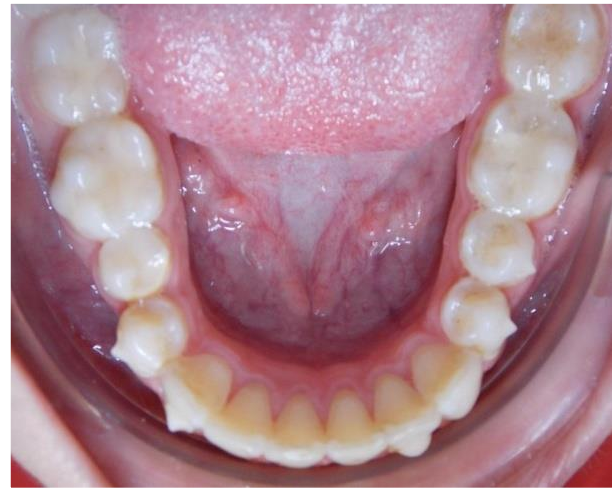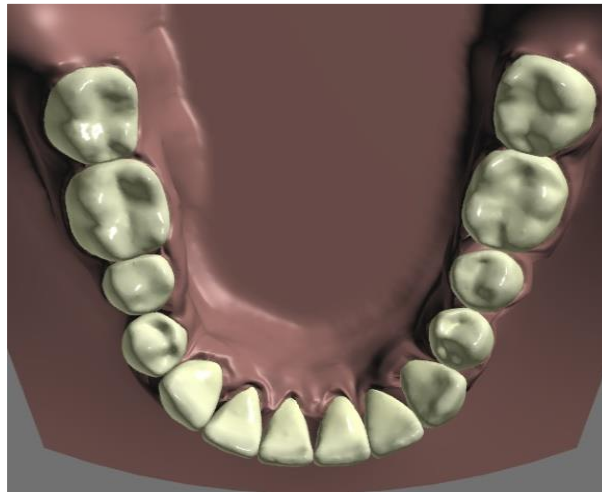
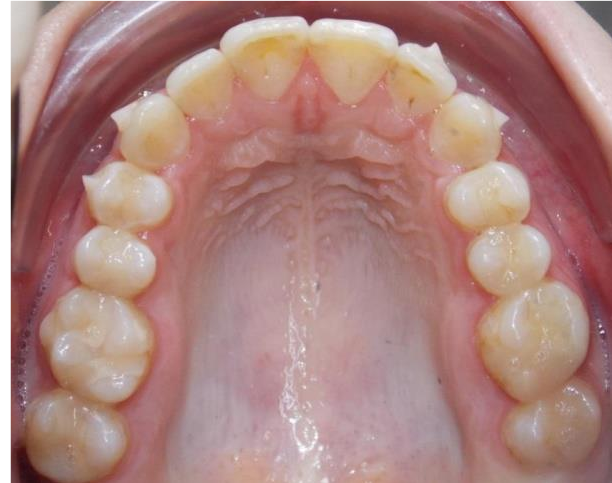
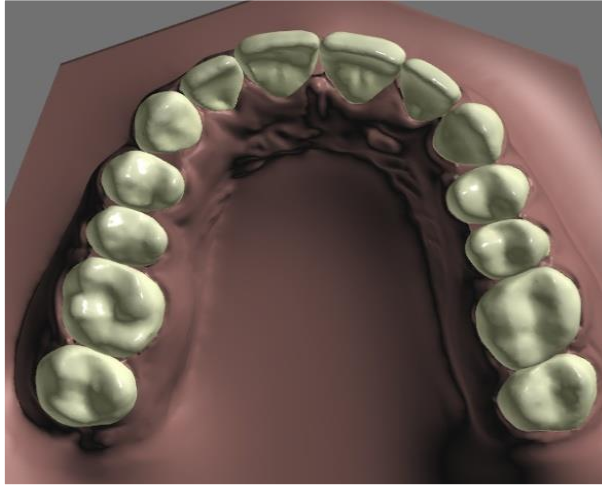
Virtual Outcome –
07.2015



Actual Outcome –
02.2016



Post Treatment – Occlusal view



Virtual Outcome – 07.2015

Actual Outcome – 02.2016